

Faculté de médecine Toulouse – Purpan

ANATOMIE  
P.C.E.M.2

# Nerfs Crâniens - Organes des Sens

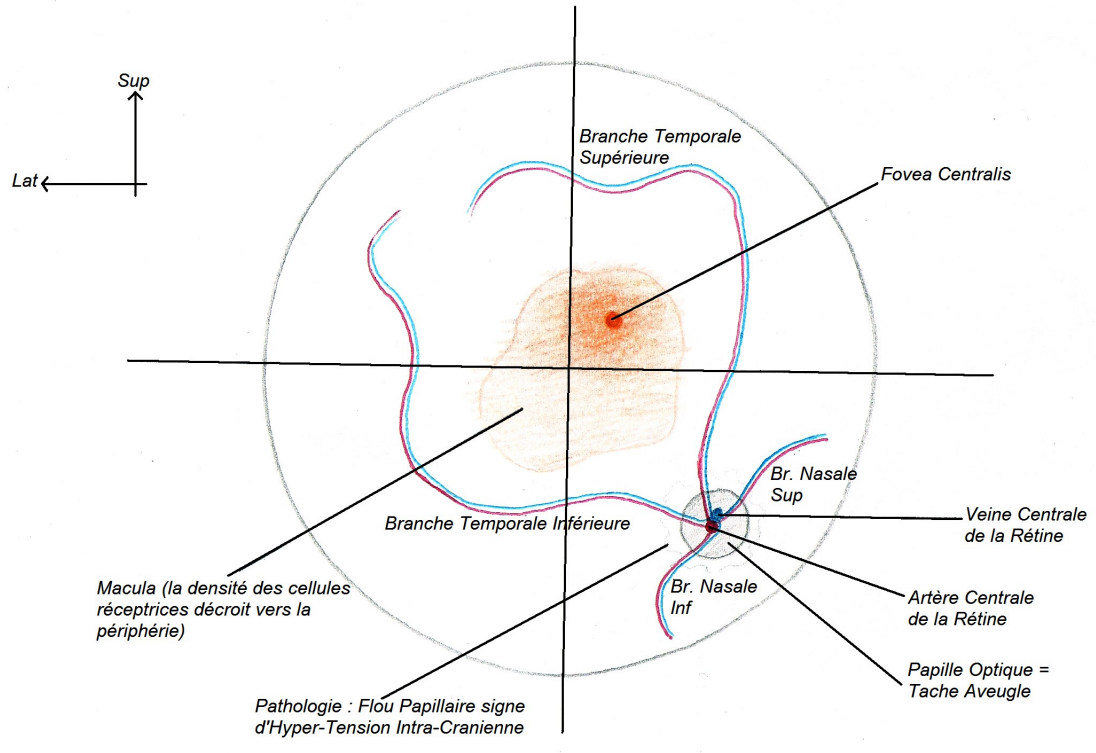
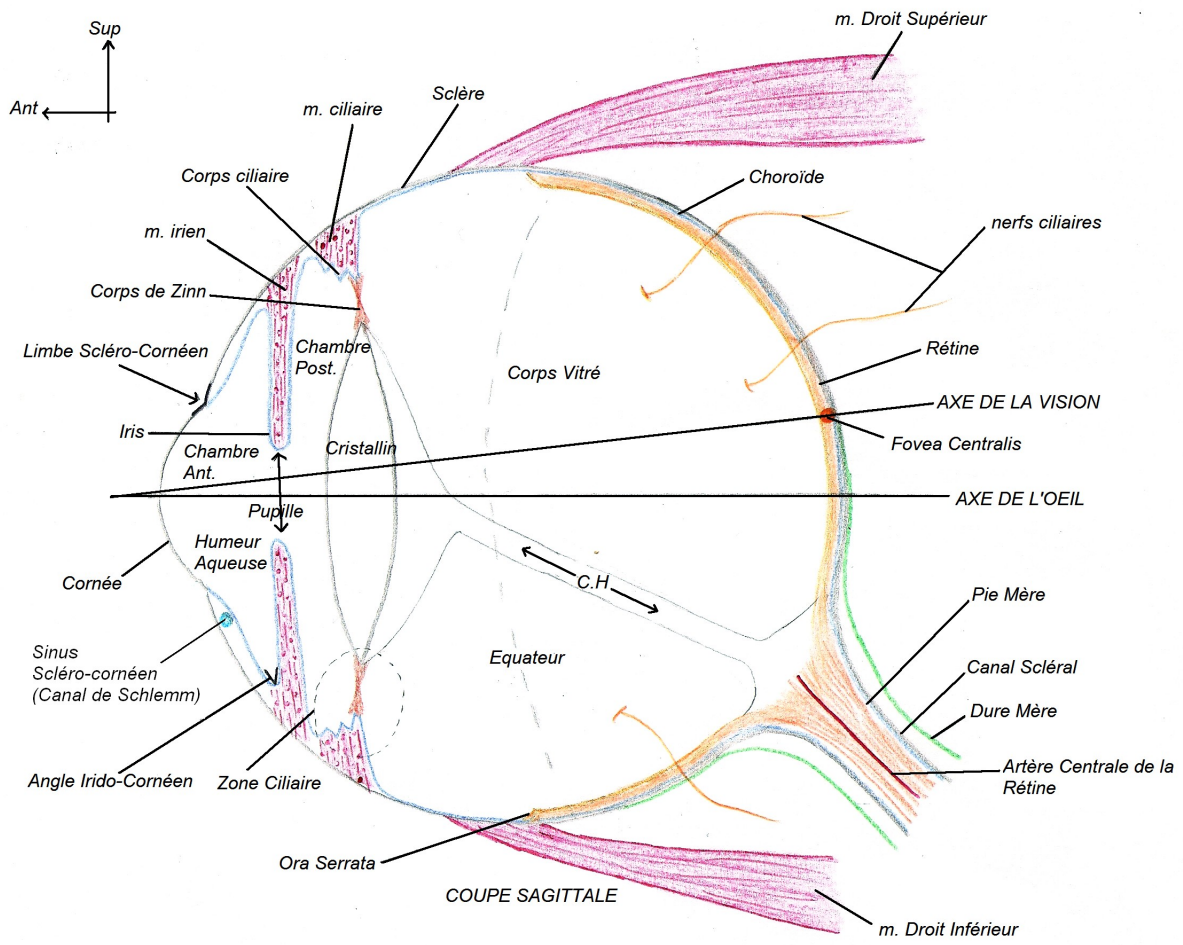
D'après les schémas et le cours du Pr. Frédéric LAUWERS

Conception et réalisation : Loïc Raoux et Gauthier Benat

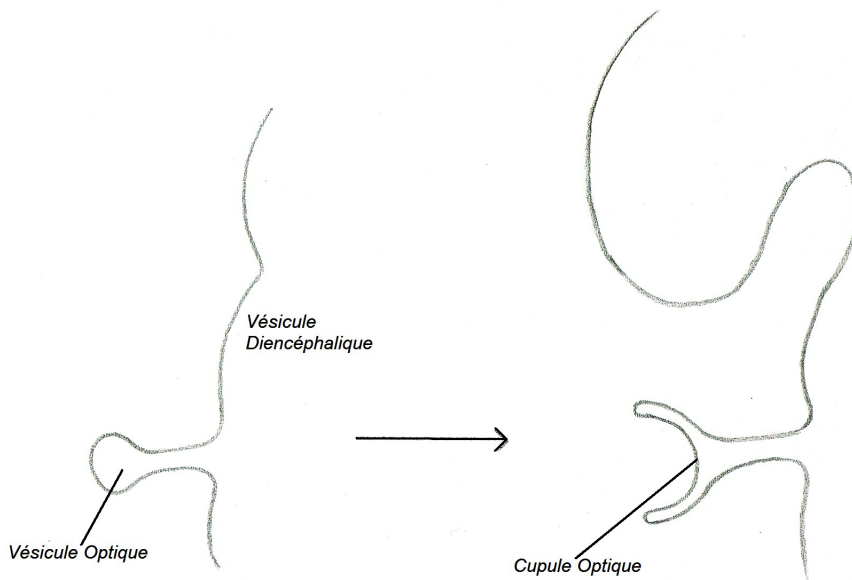
# Organes des Sens

-

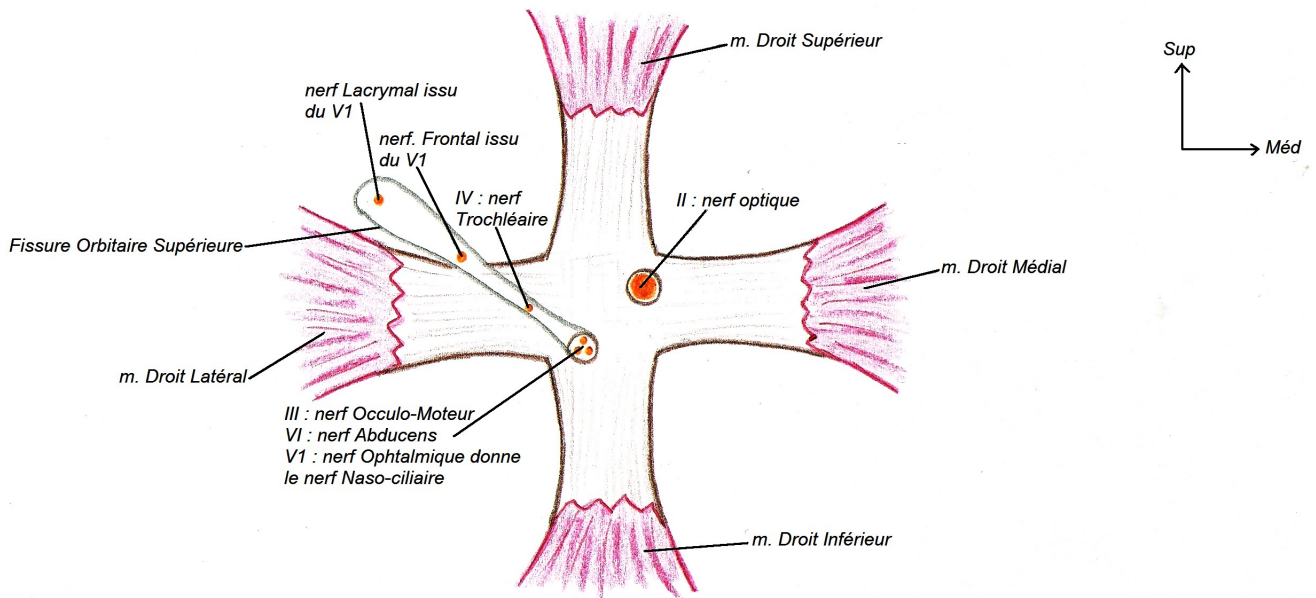
# Appareil de la Vision



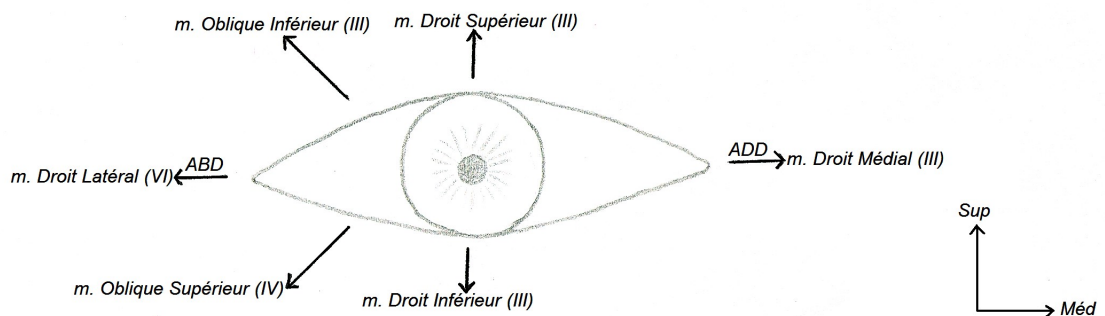
EXAMEN du FOND de L'OEIL



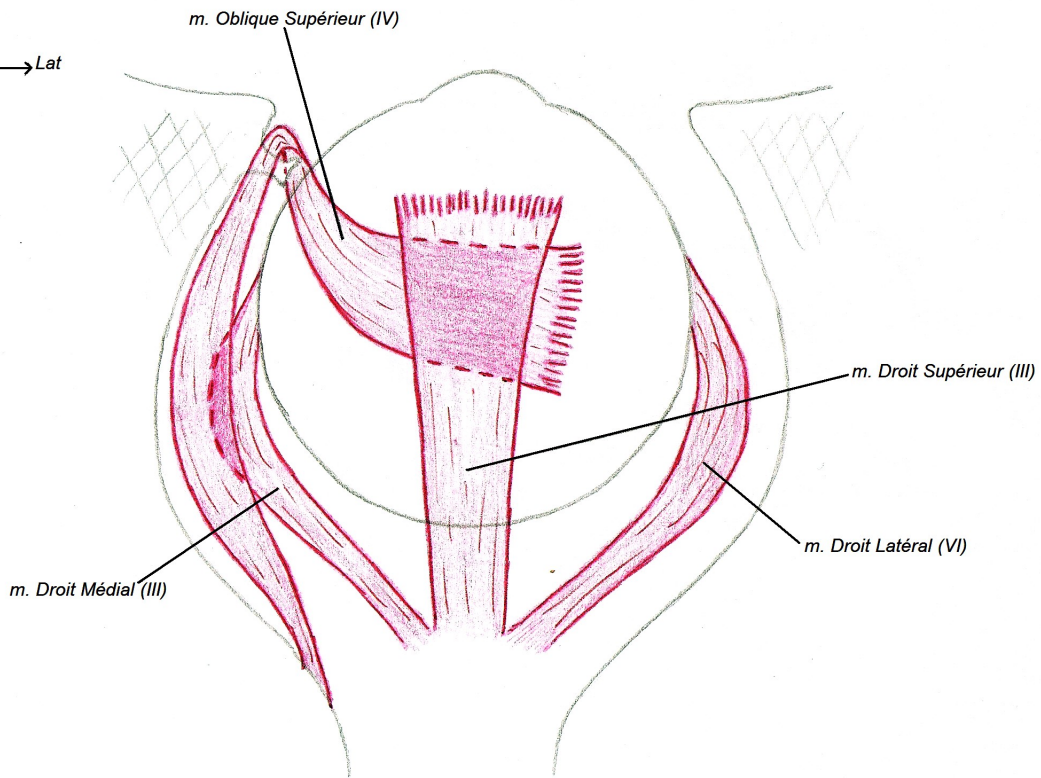
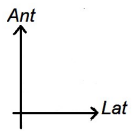
**EMBRYOGENESE de la RETINE**



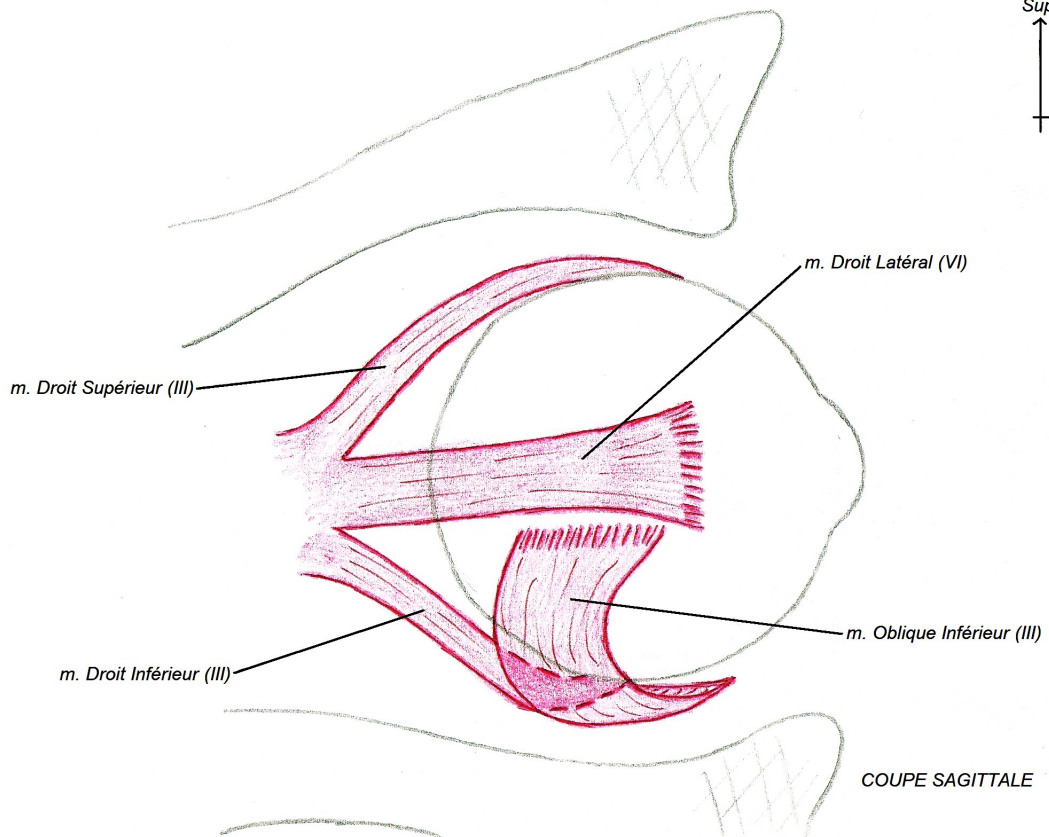
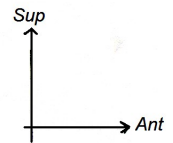
**Les MUSCLES DROITS**



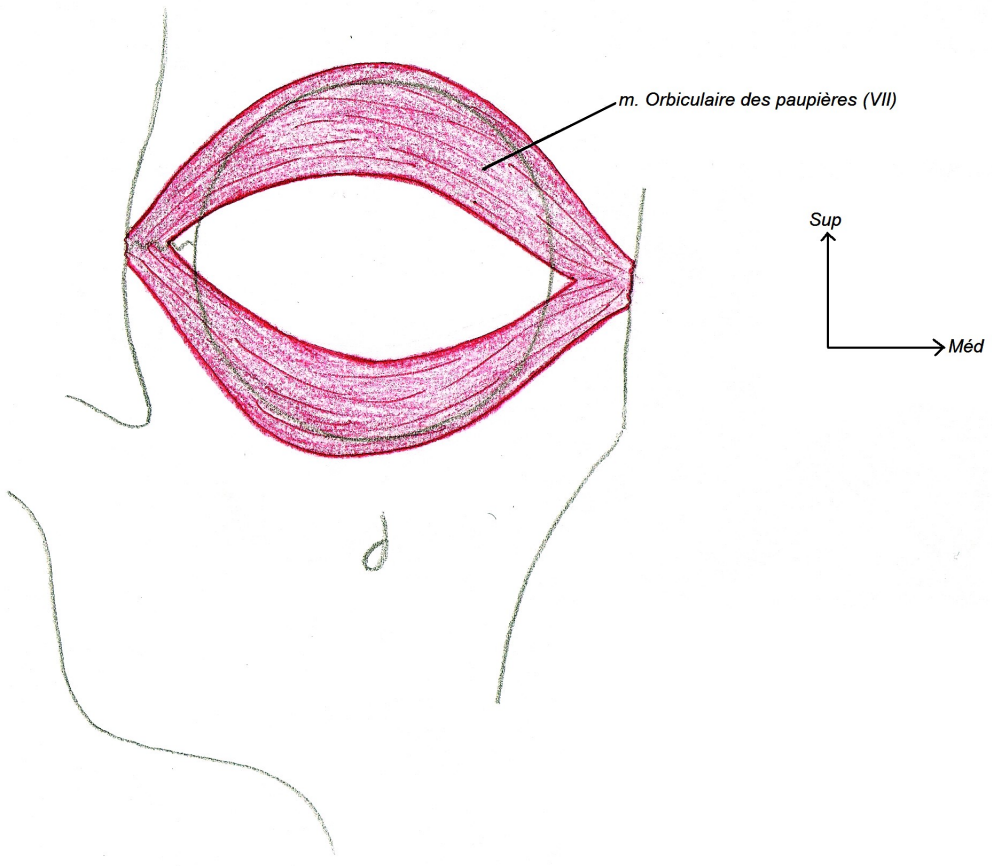
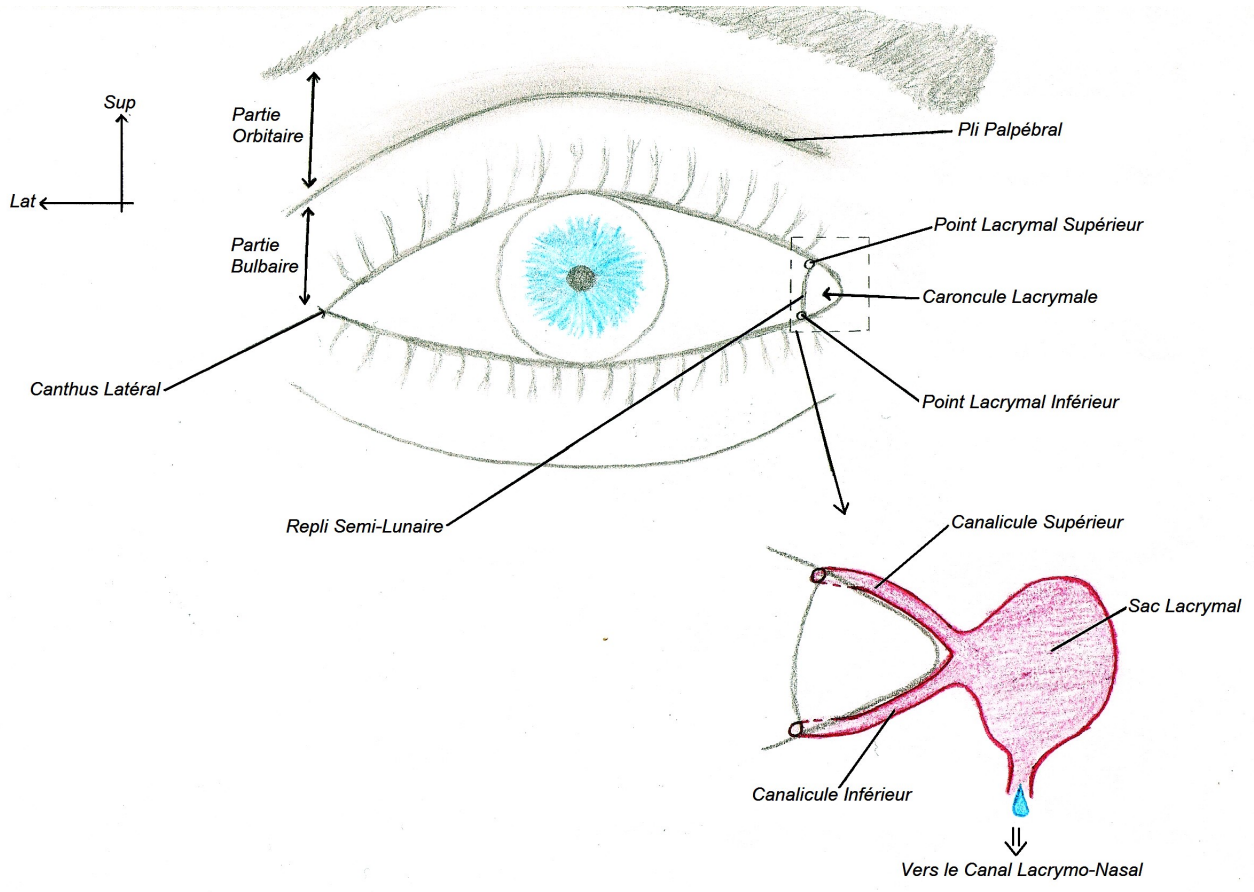
**Les MOUVEMENTS de L'OEIL**

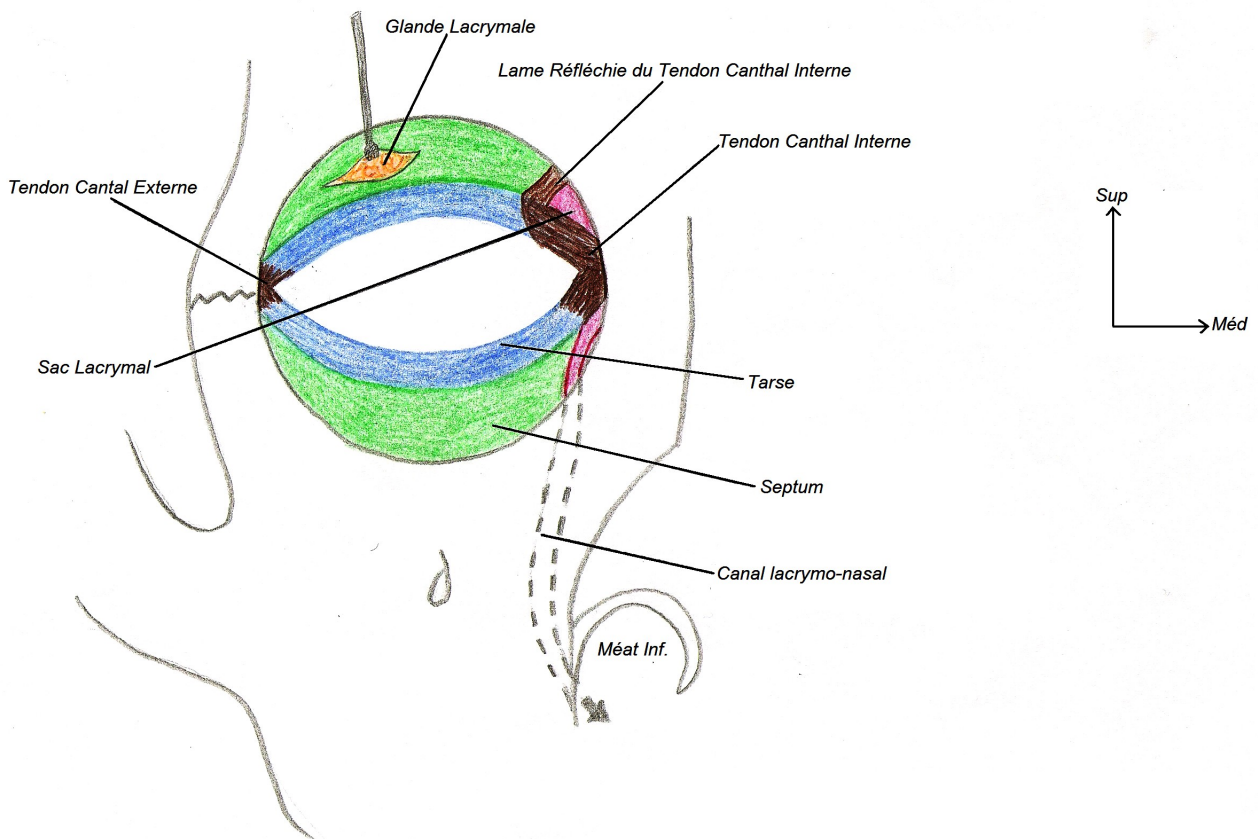
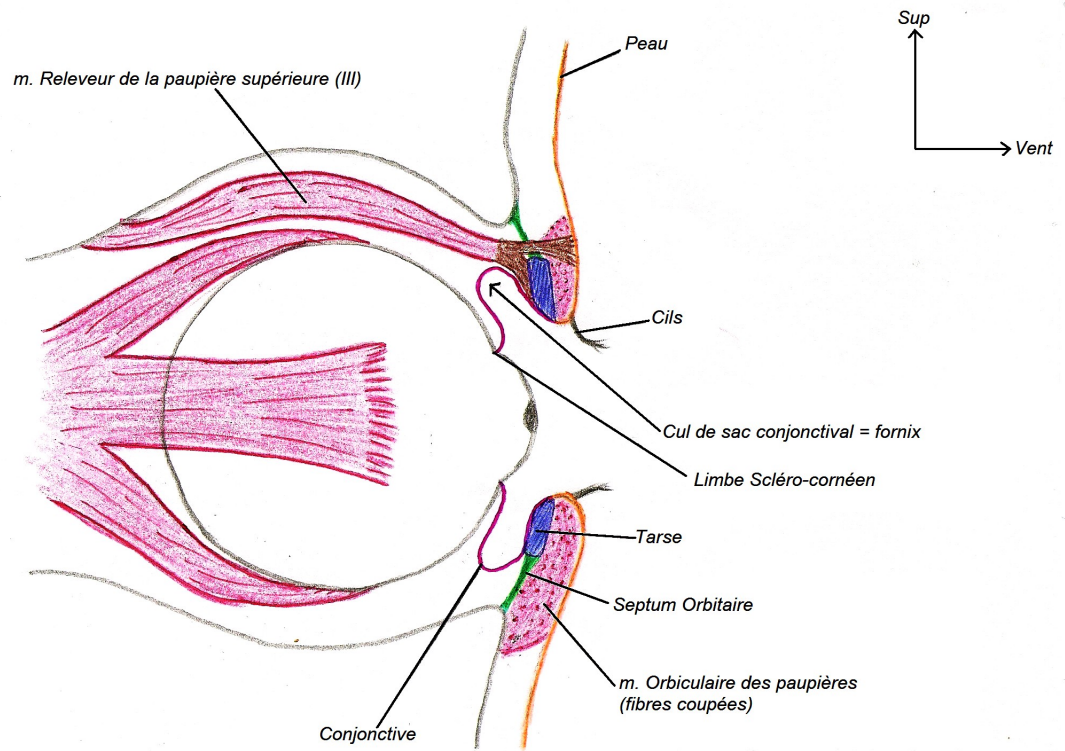


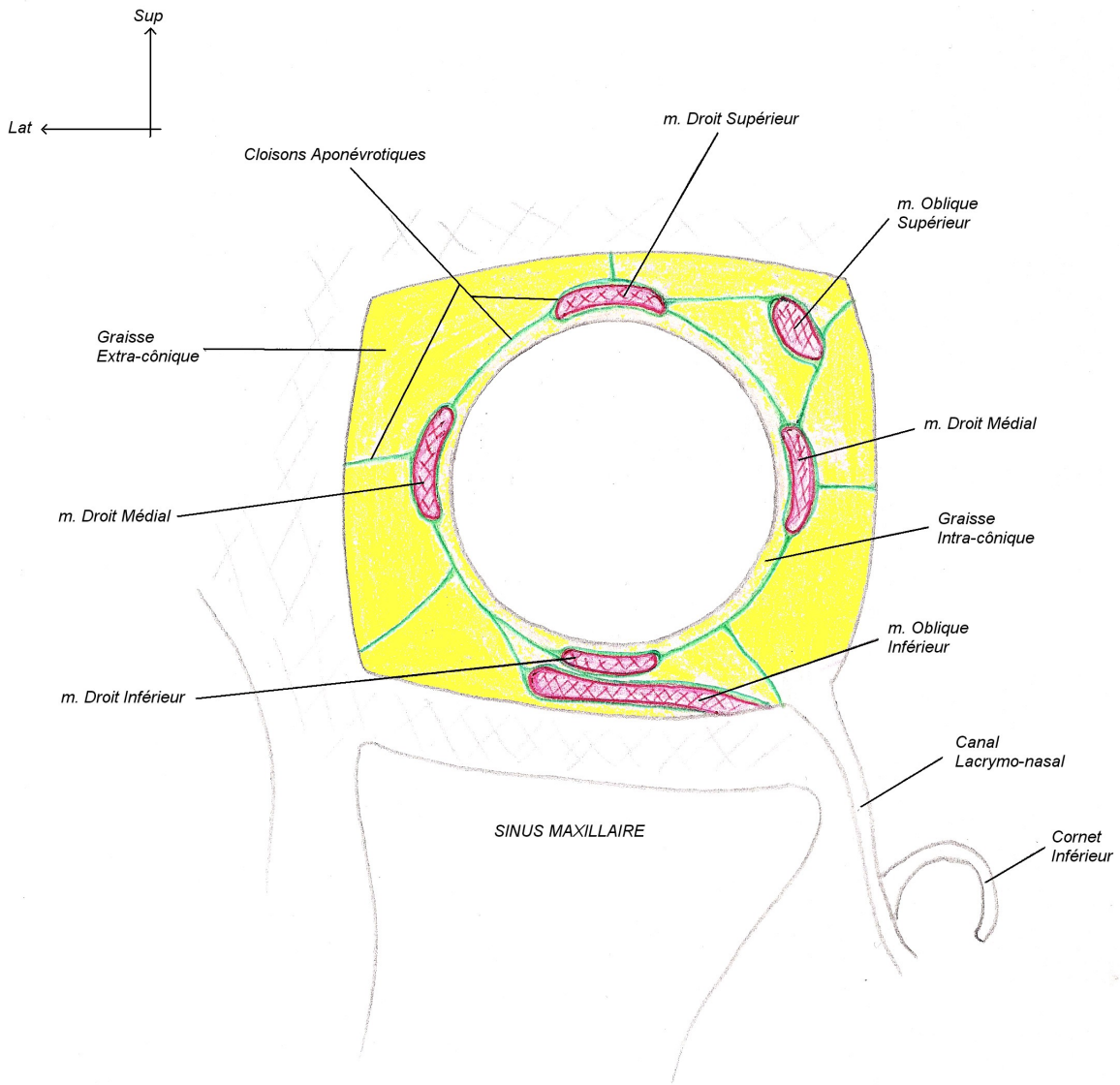
COUPE HORIZONTALE (vue supérieure)



COUPE SAGITTALE





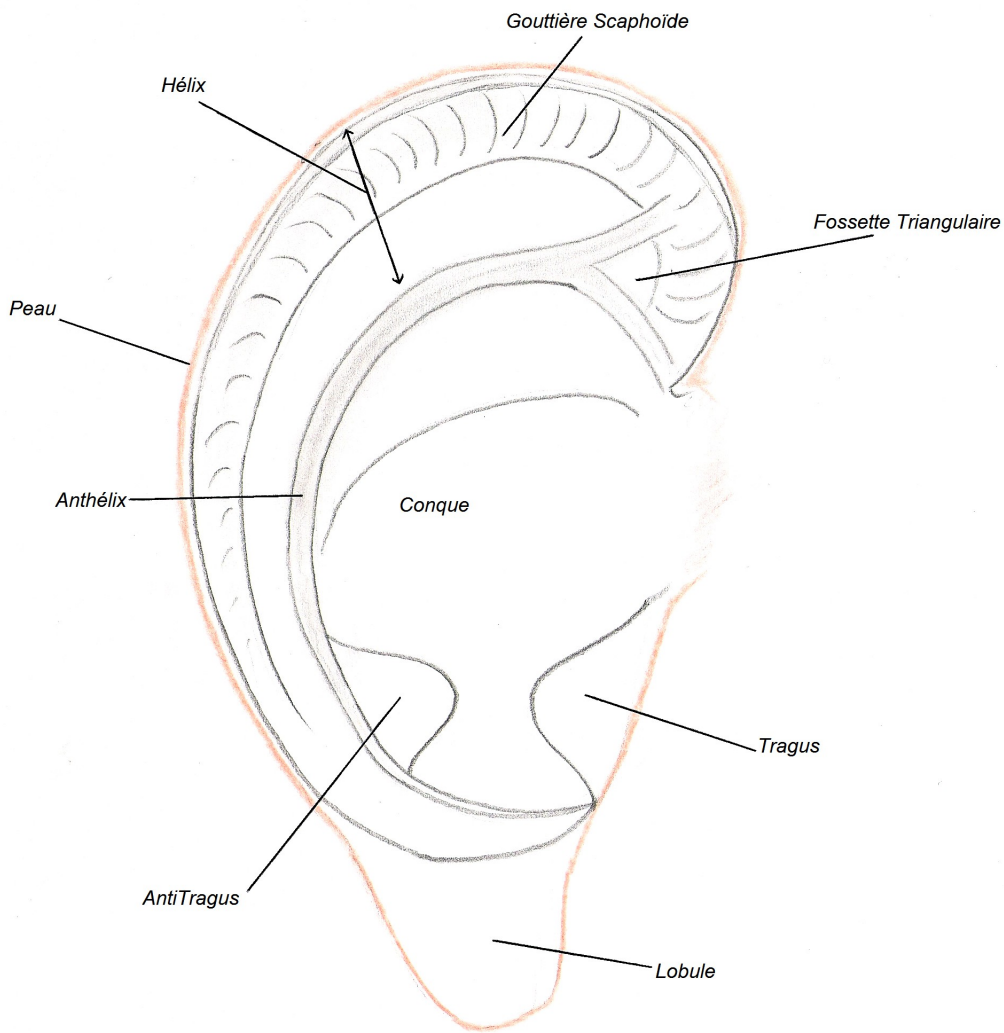


COUPE FRONTALE (Vue Ventrale)

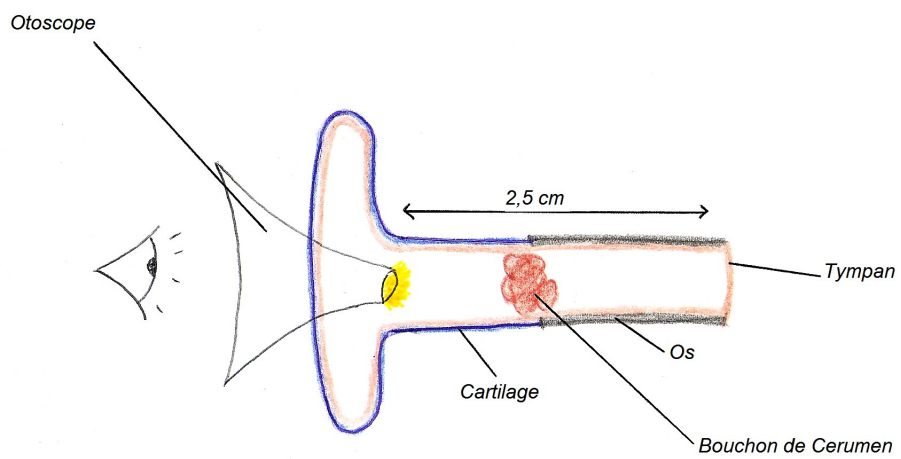
# Organes des Sens

-

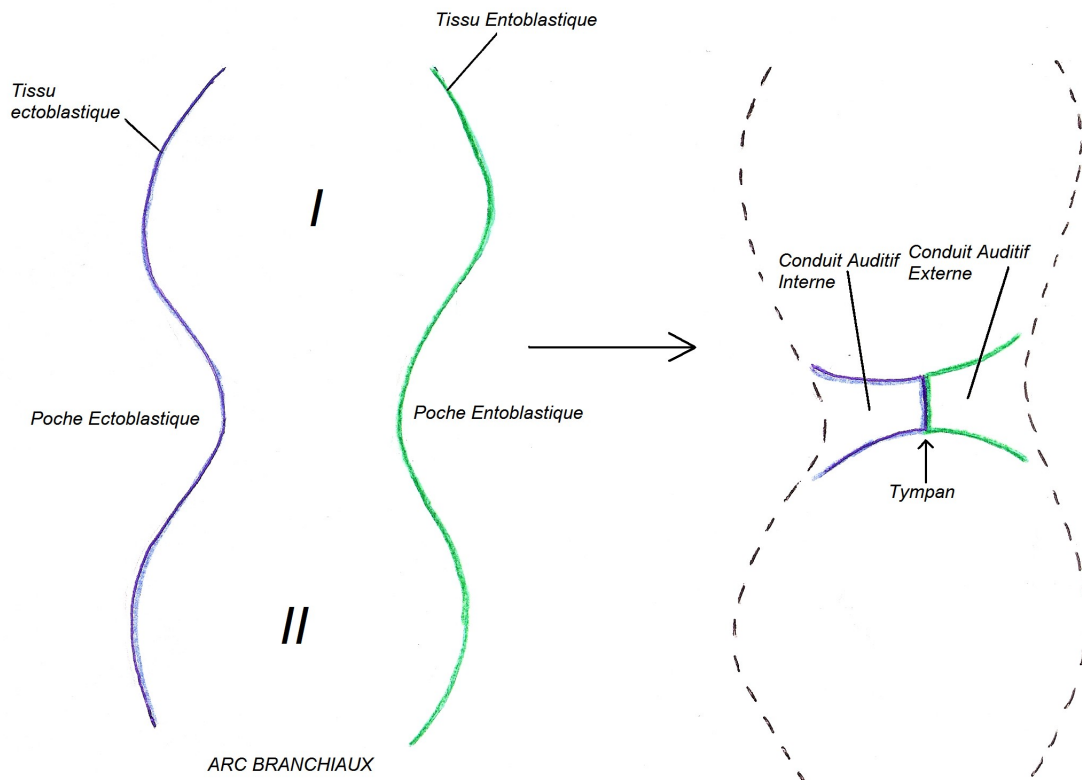
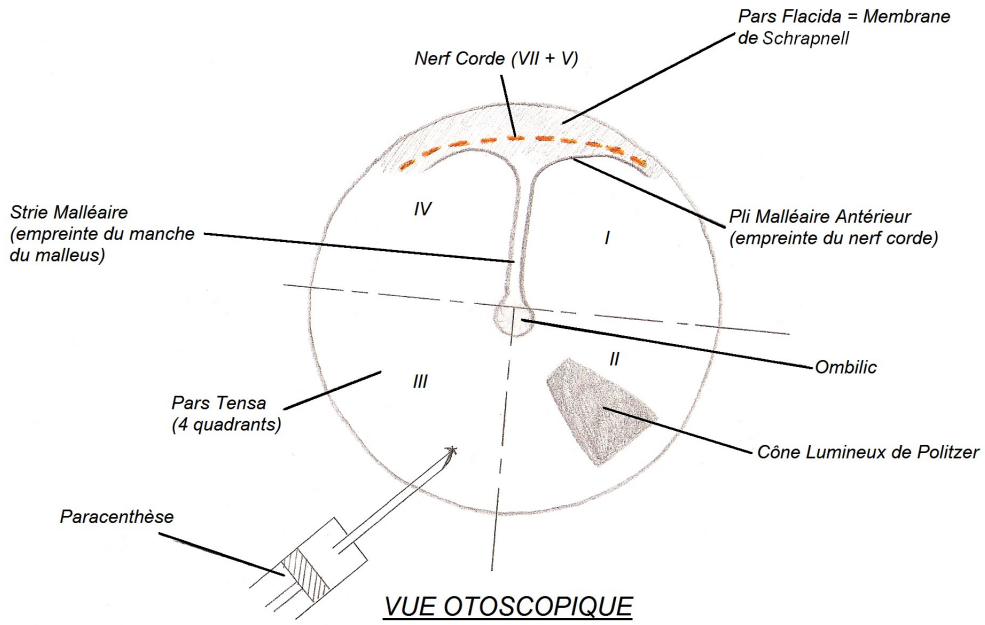
# Appareil de l'Audition

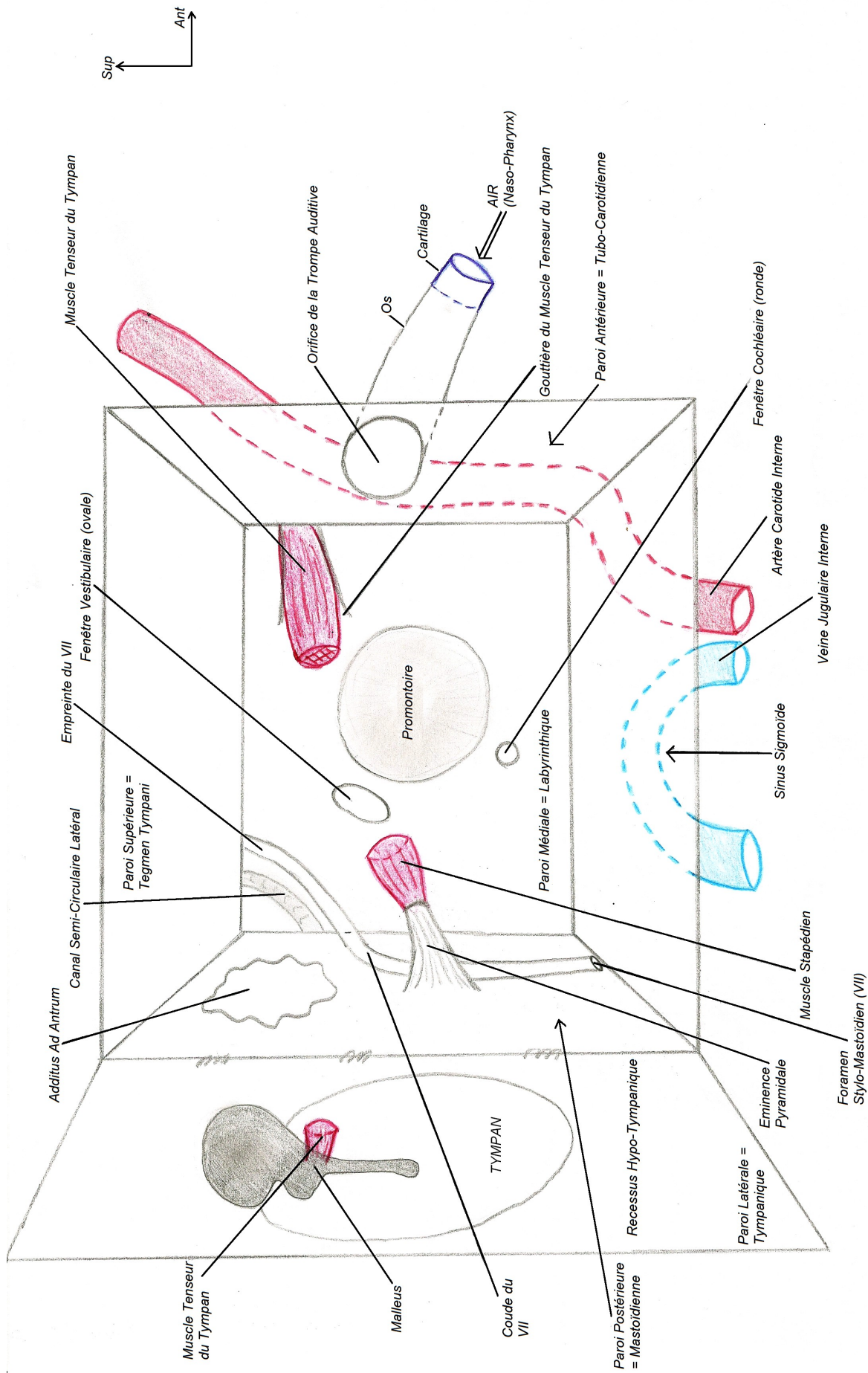


LE PAVILLON DE L'OREILLE

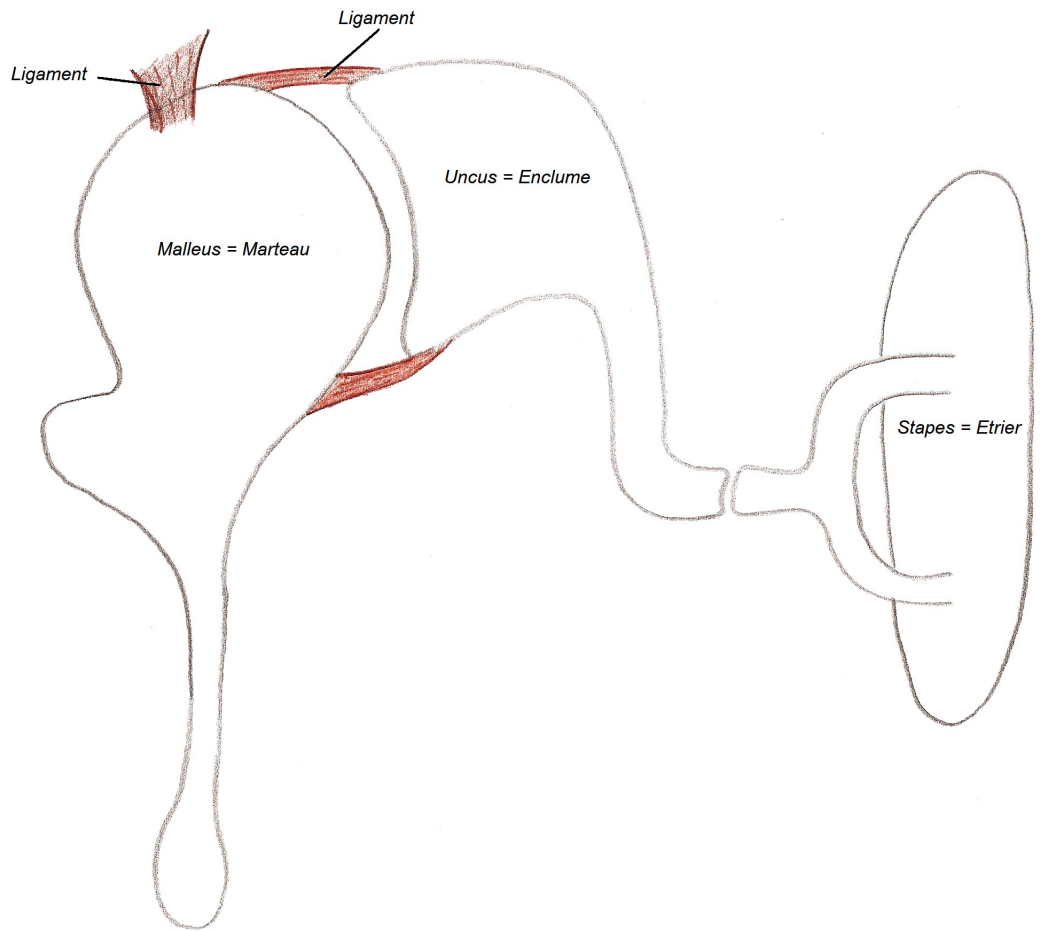


LE CONDUIT AUDITIF EXTERNE

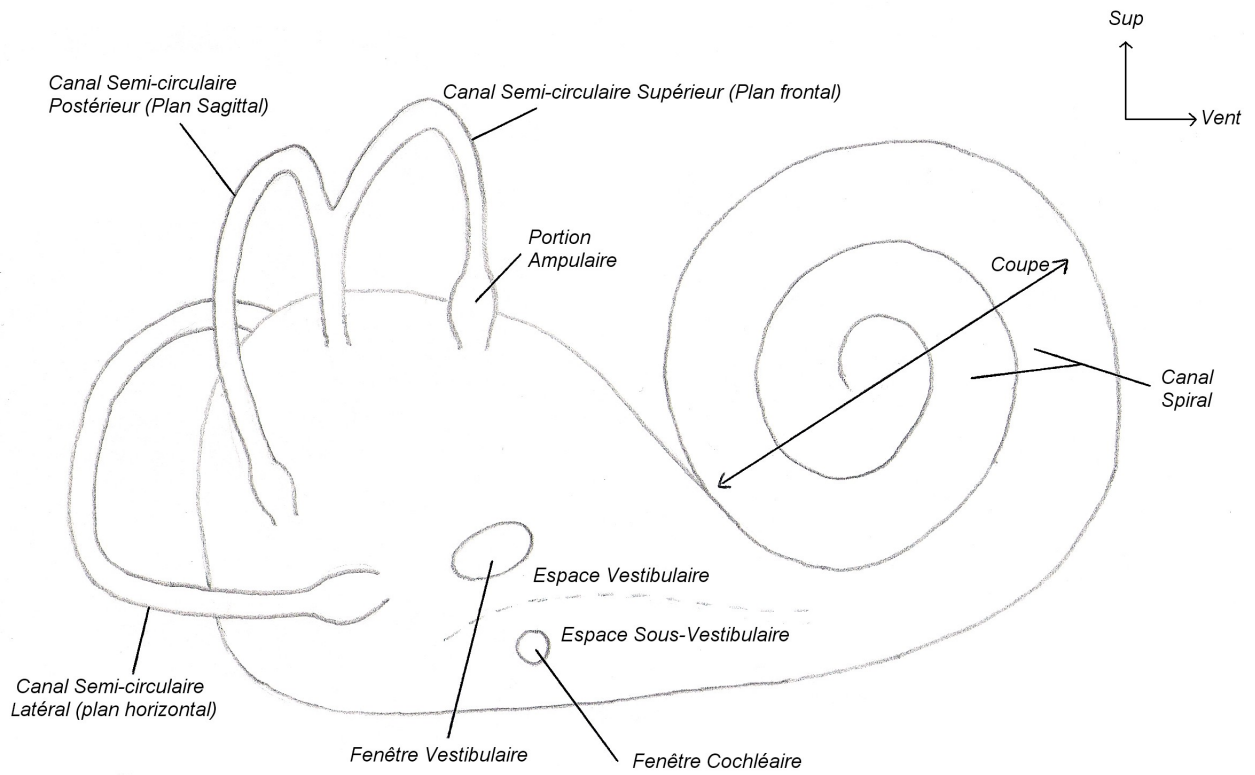




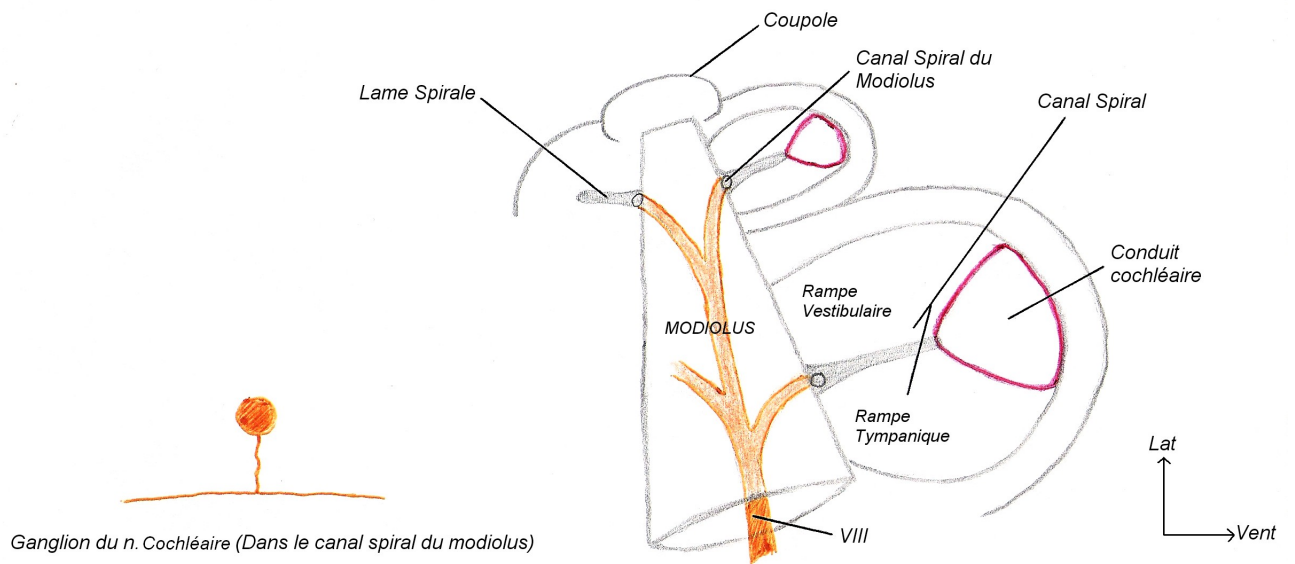
**L'OREILLE MOYENNE (VUE LATÉRALE)**  
 après ouverture de la paroi latérale



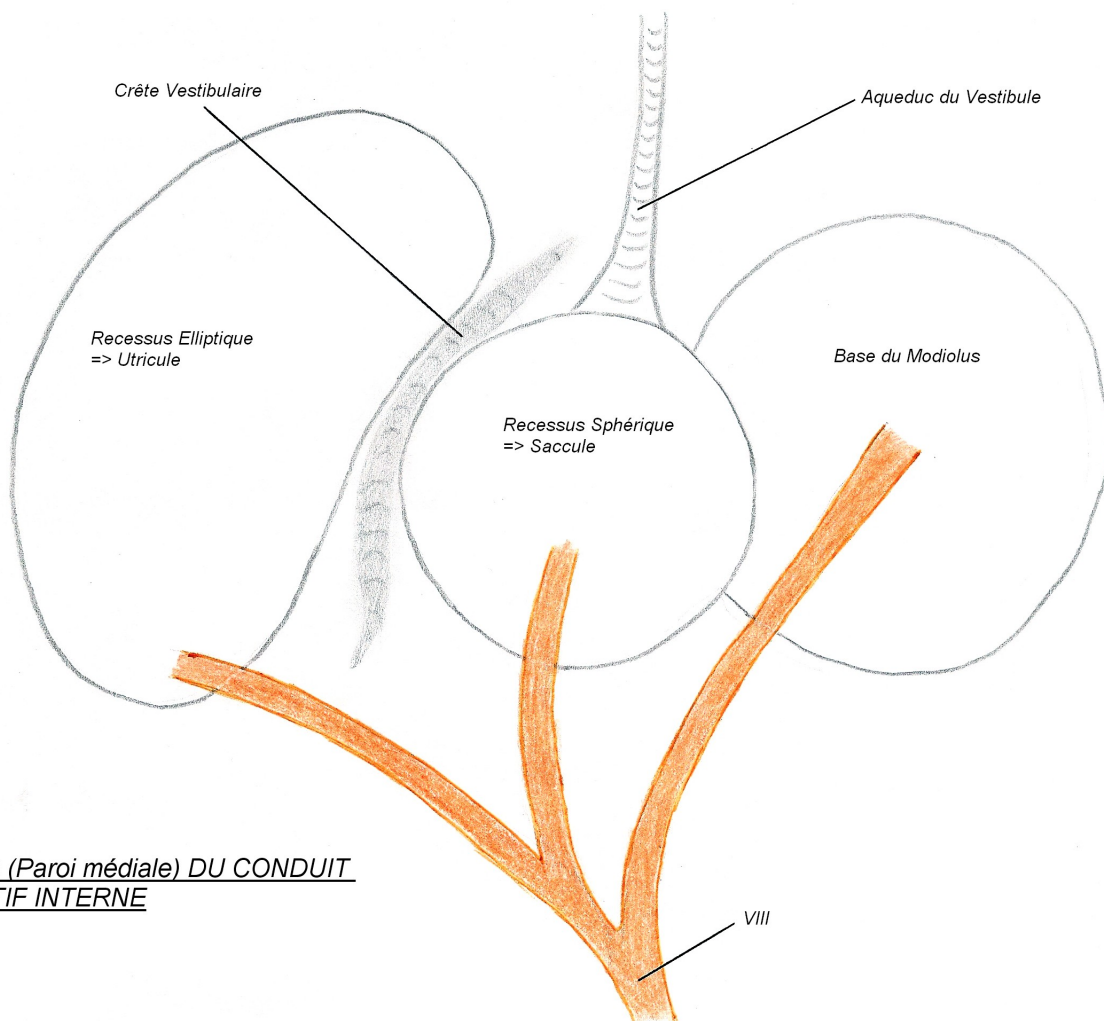
LA CHAÎNE OSSICULAIRE



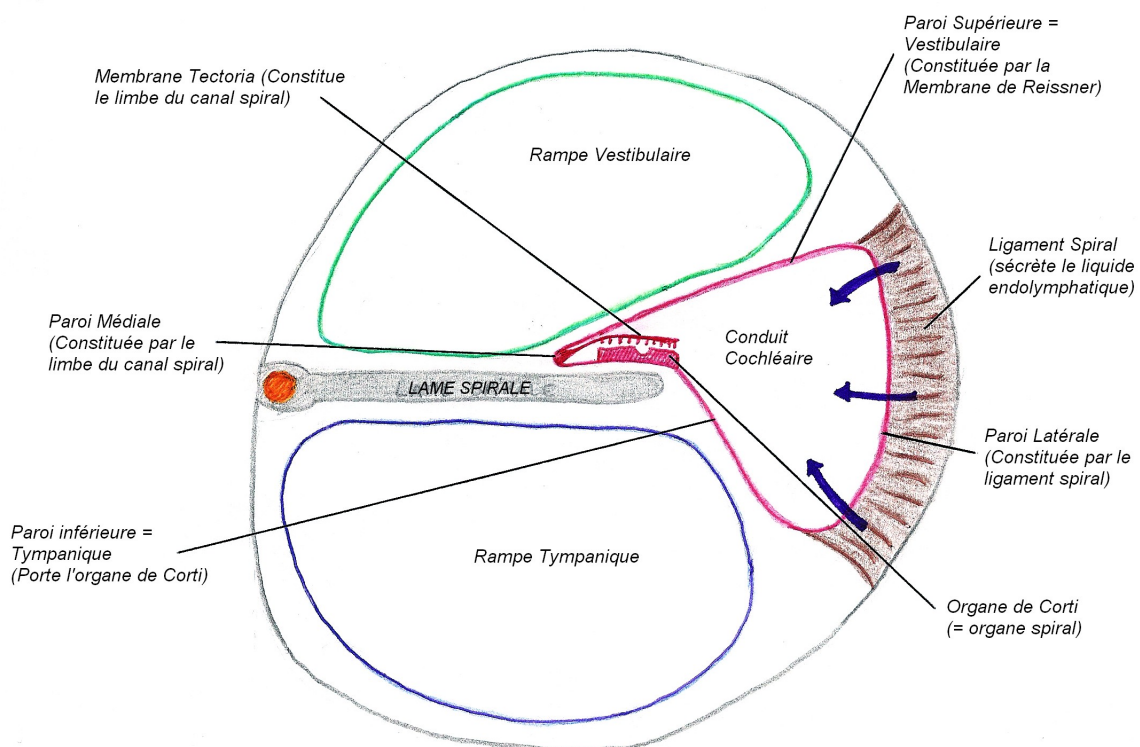
LE LABYRINTHE OSSEUX (Vue latérale)



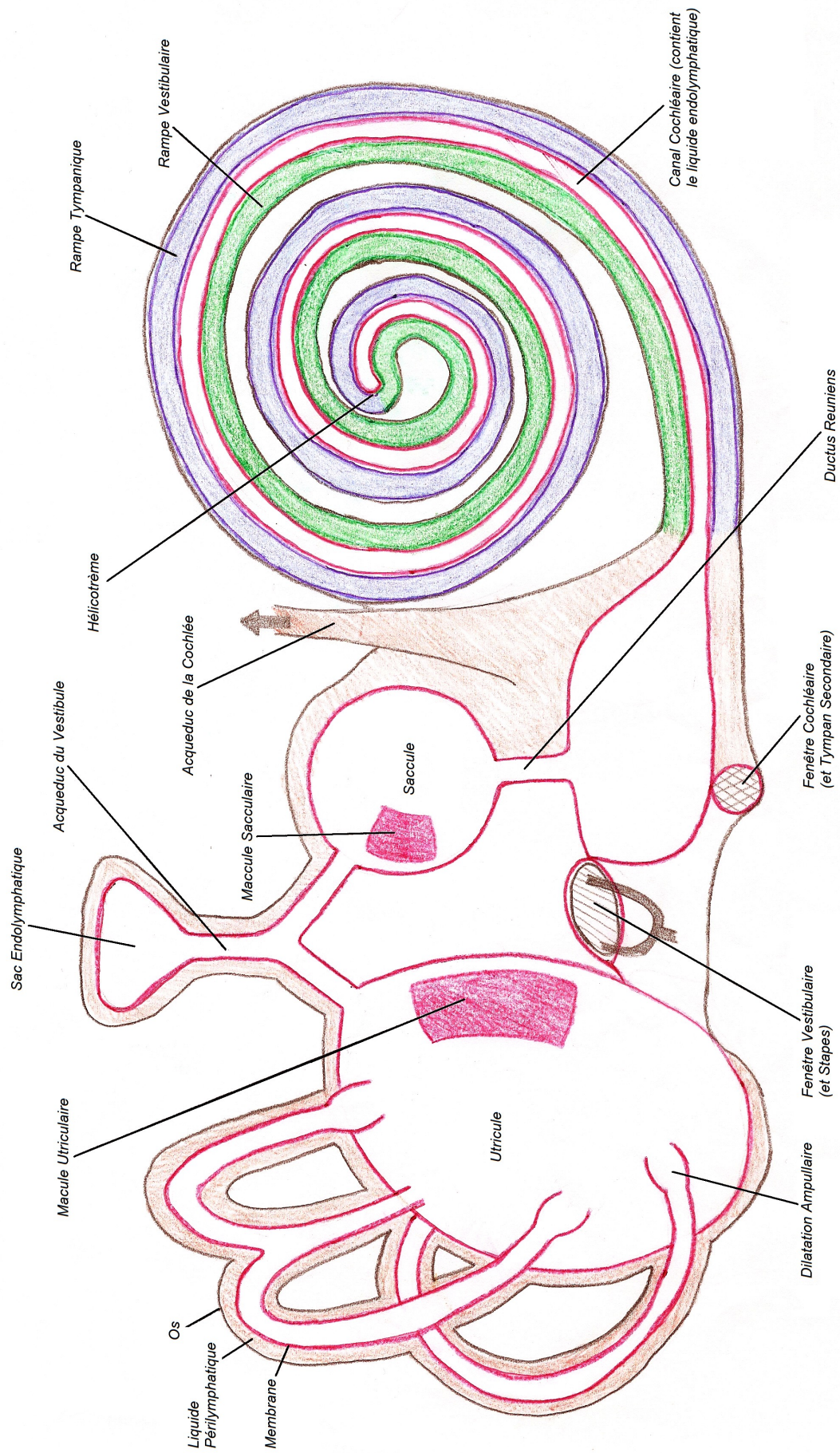
COUPE DE LA COCHLEE



FOND (Paroi médiale) DU CONDUIT AUDITIF INTERNE



CLOISONNEMENT DU CANAL SPIRAL



**LE LABYRINTHE MEMBRANEUX**