

Faculté de médecine Toulouse – Purpan

ANATOMIE
P.C.E.M.2

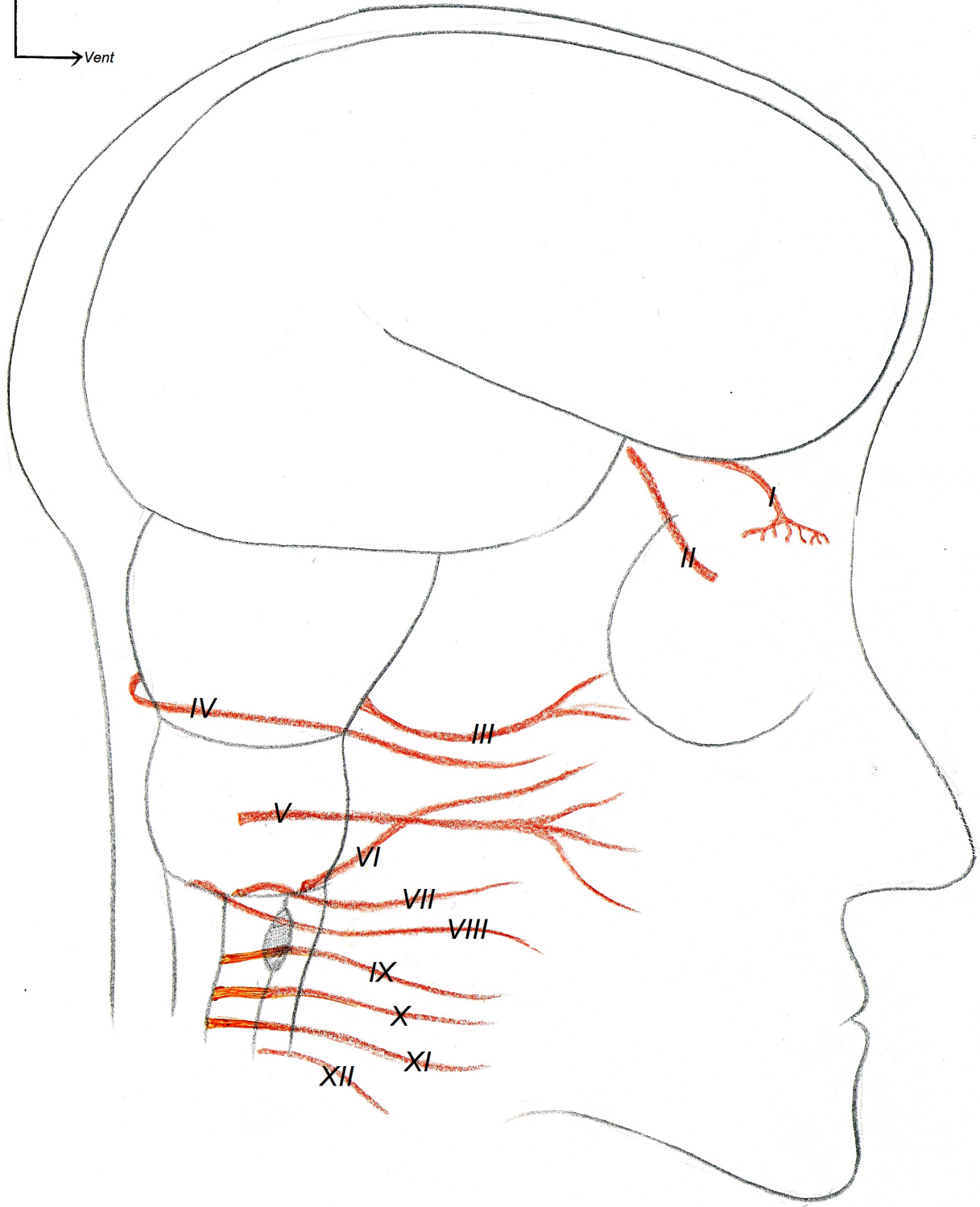
Nerfs Crâniens - Organes des Sens

D'après les schémas et le cours du Pr. Frédéric LAUWERS

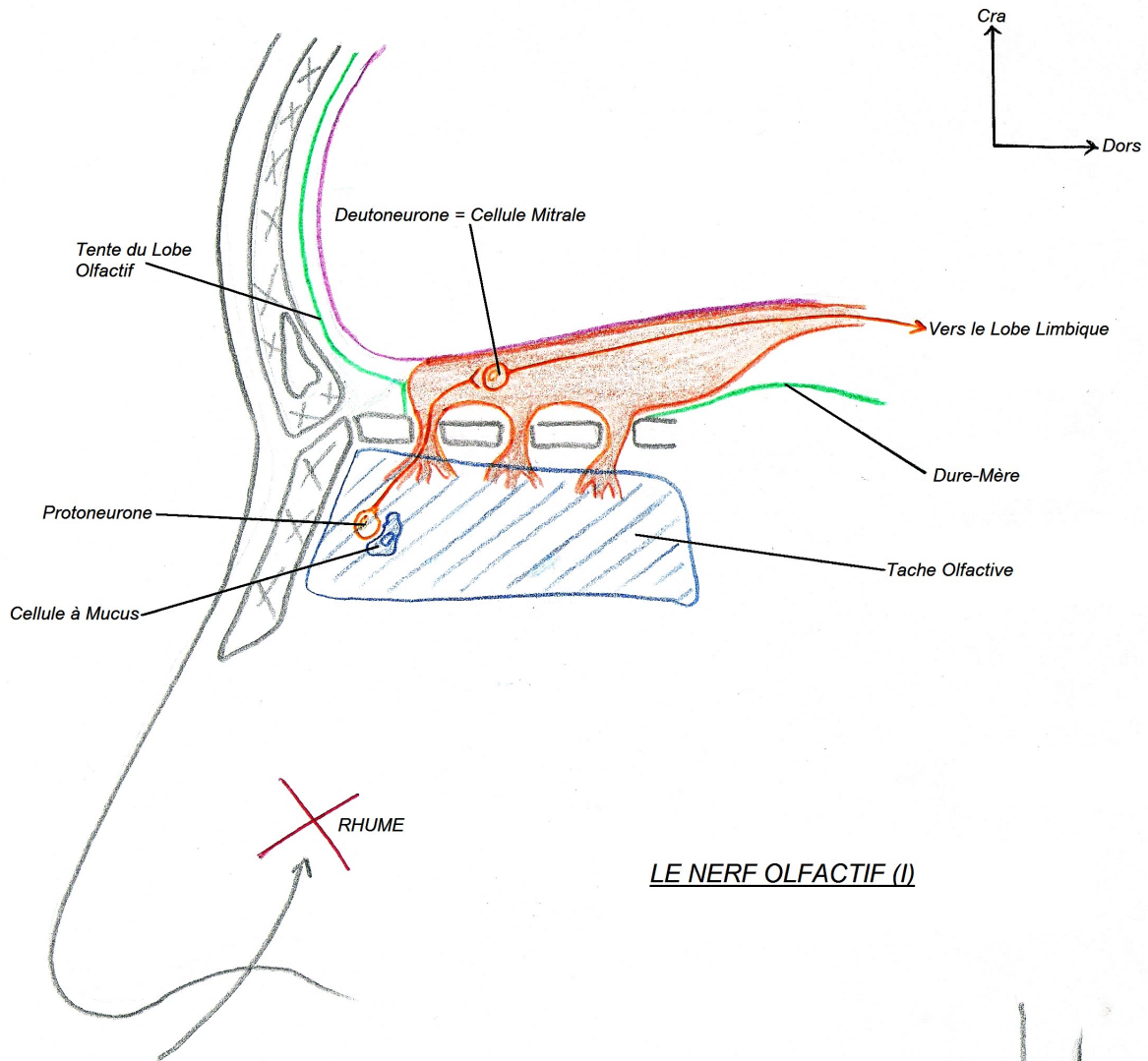
Conception et réalisation : Loïc Raoux et Gauthier Benat

Nerfs Crâniens

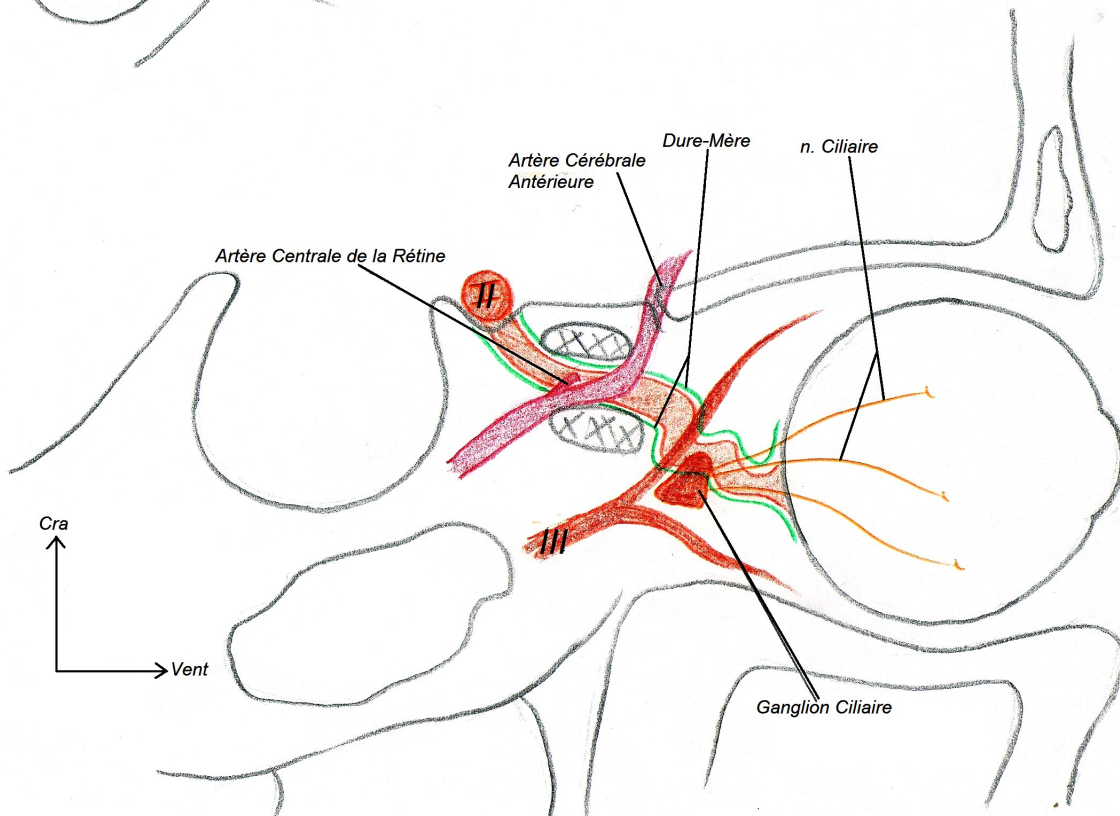
Cra
Vent

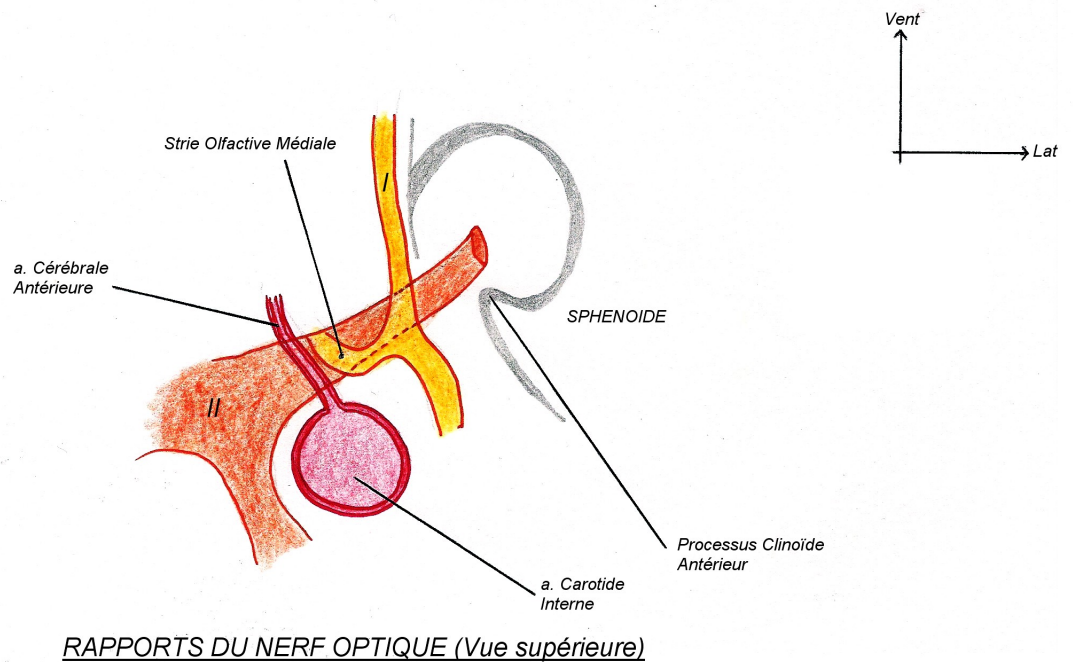
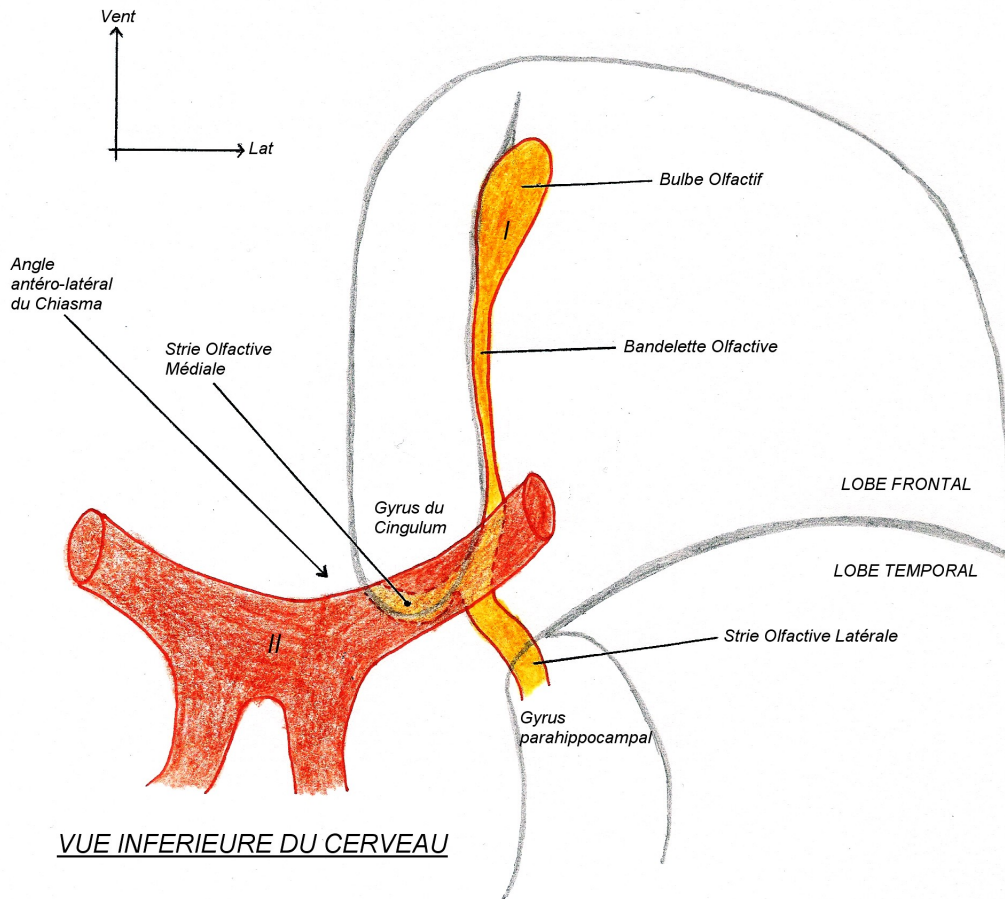


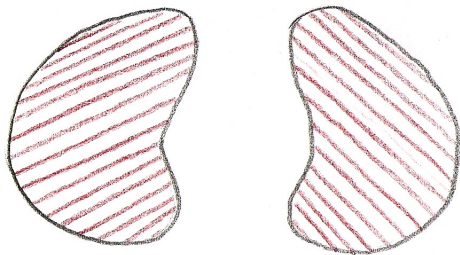
ORIGINE APPARENTE DES NERFS CRANIENS



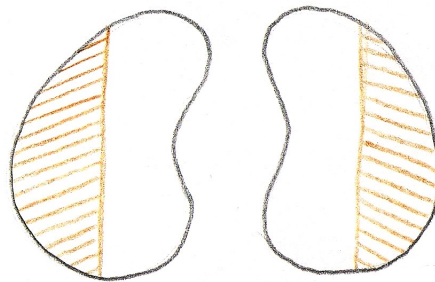
LE NERF OLFACTIF (I)








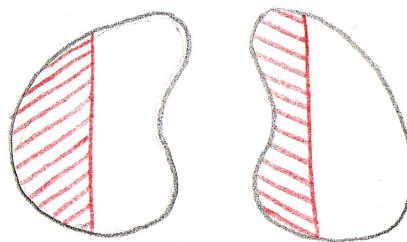
CECITE
(lésion totale des nerfs optiques)



HEMI-ANOPSIE BI-TEMPORALE
Compression / Section du Chiasma



HEMI-ANOPSIE NASALE DROITE
(compression partie latérale du chiasma)



HEMI-ANOPSIE LATERALE HOMONYME
Compression / Section du Tractus



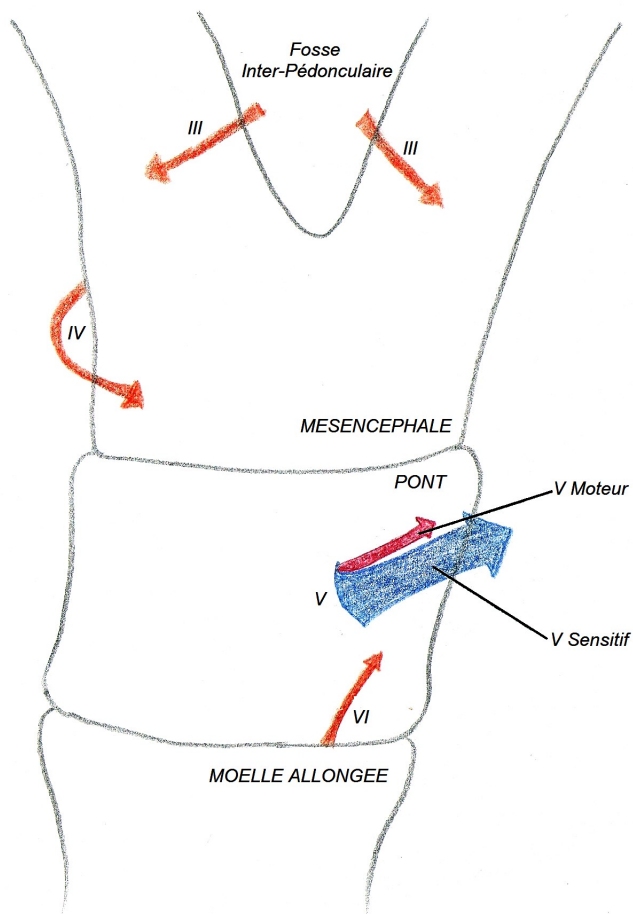
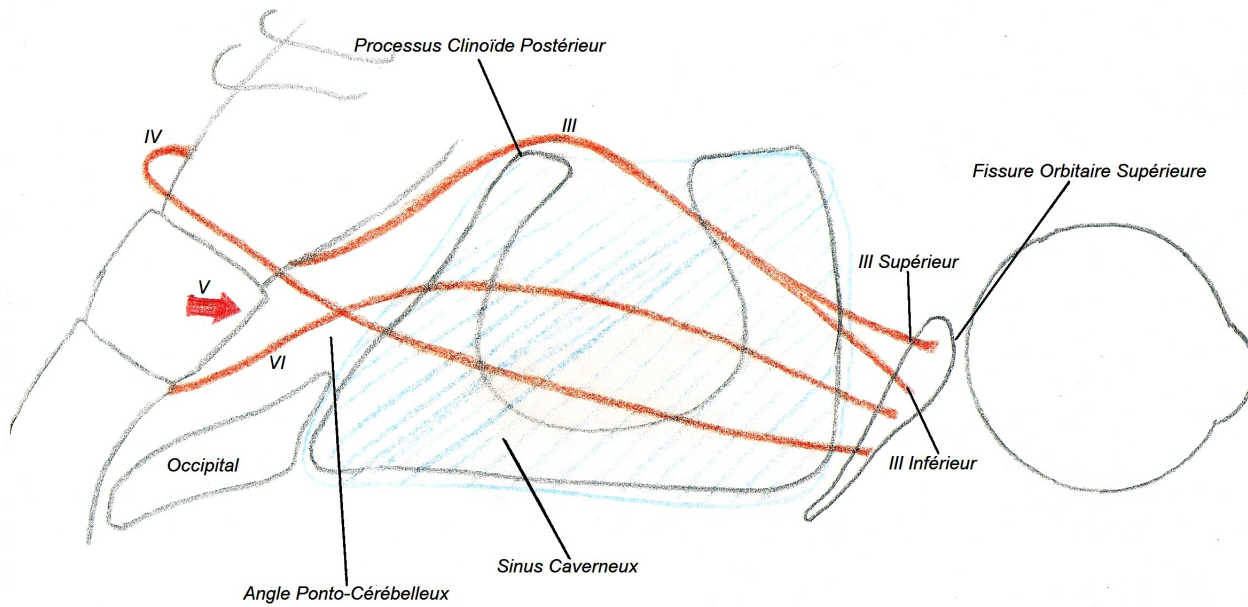
STRABISME DIVERGEANT
(lésion du III)

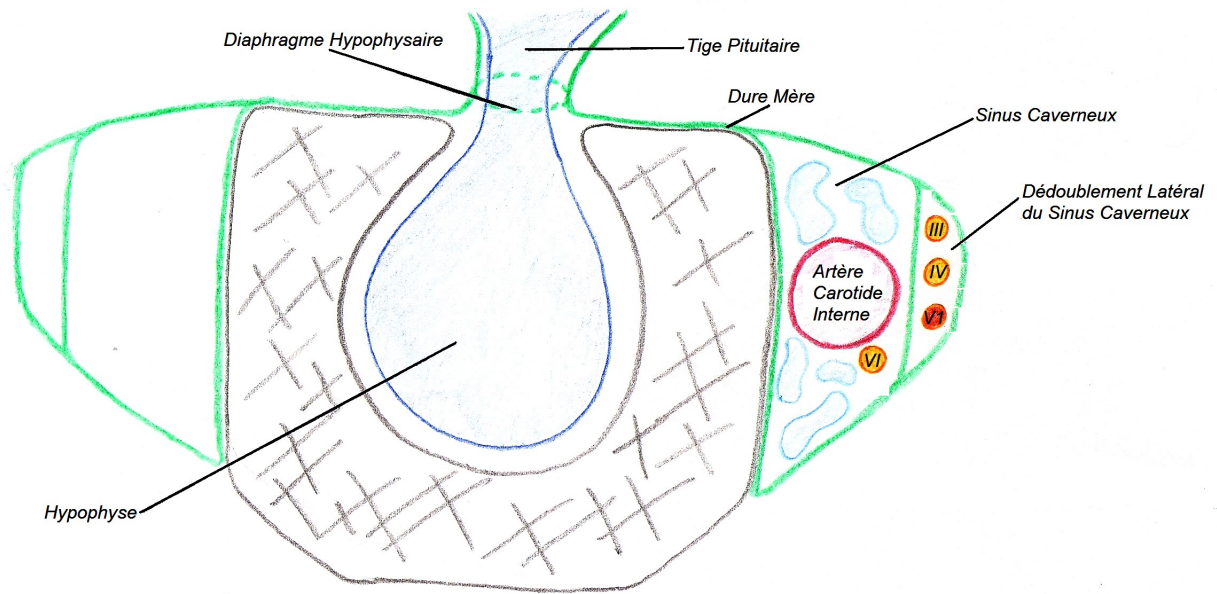


AXE VISUEL EN HAUT ET EN DEDANS
(lésion du IV)

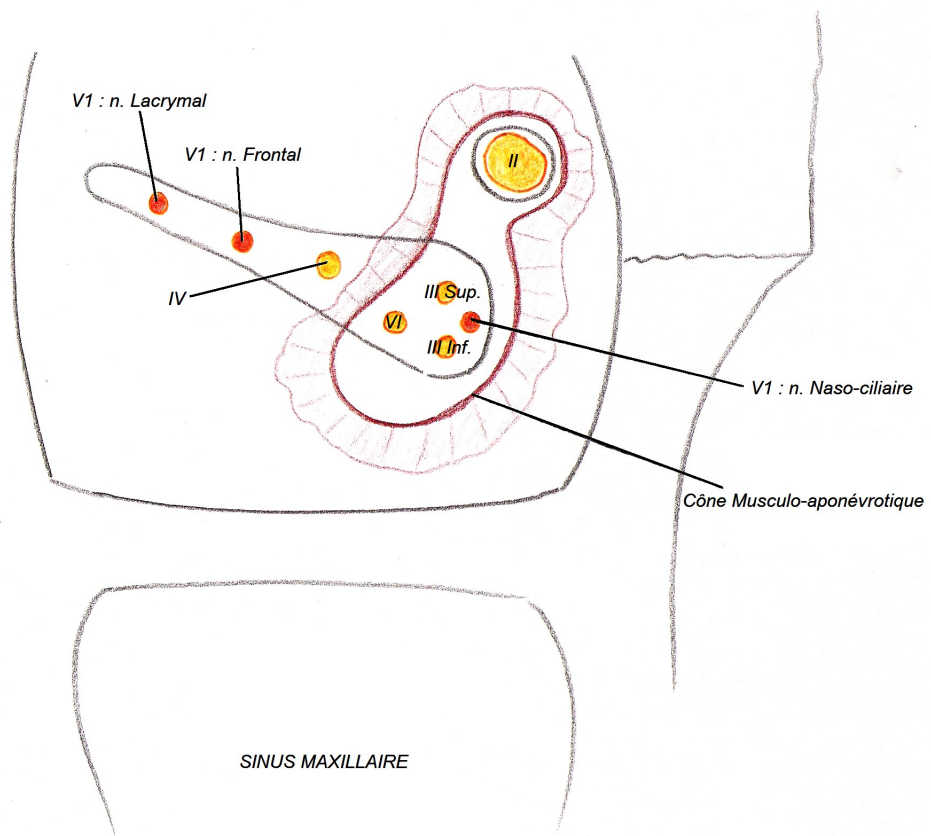


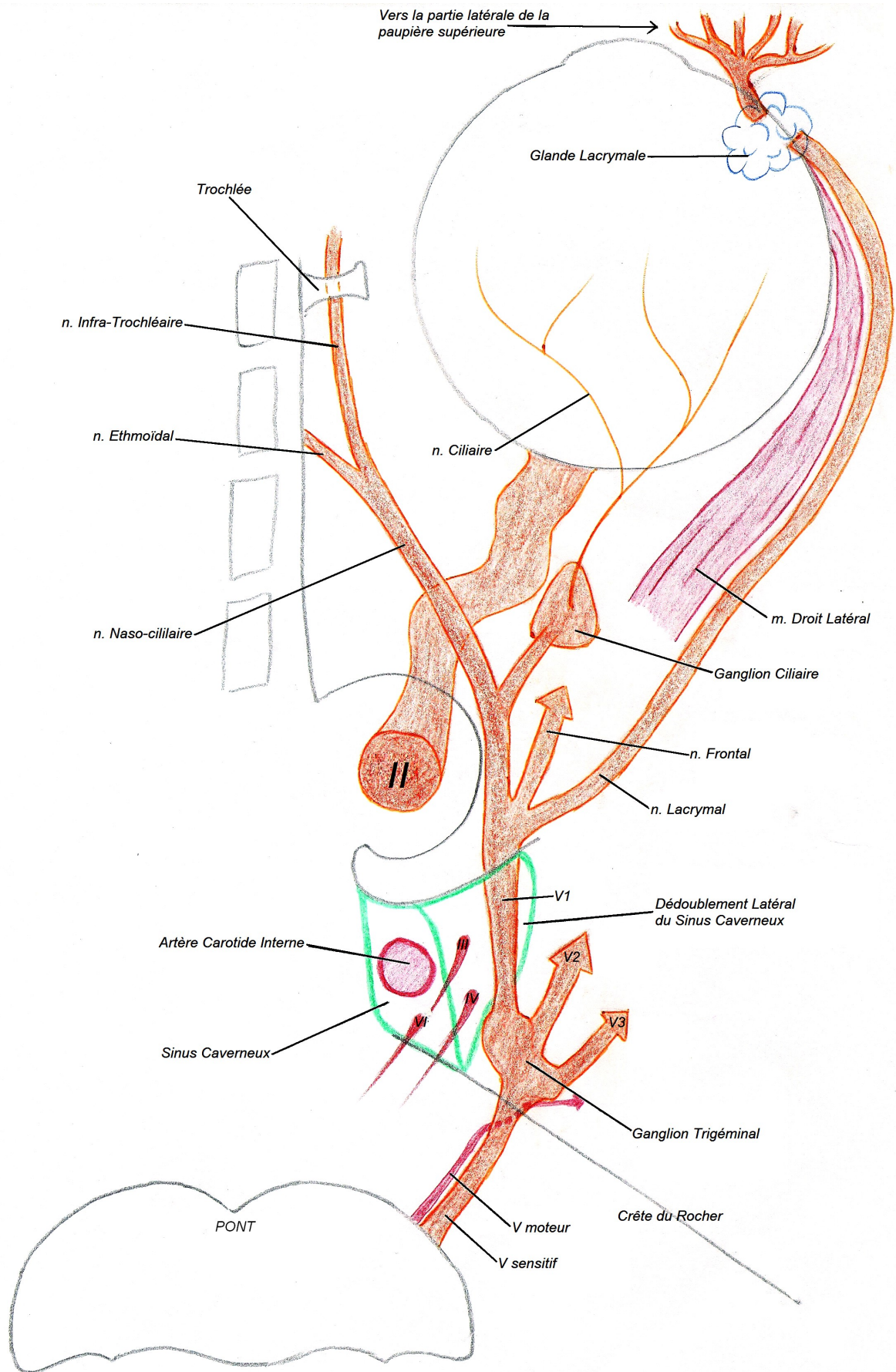
STRABISME CONVERGEANT
(lésion du VI)

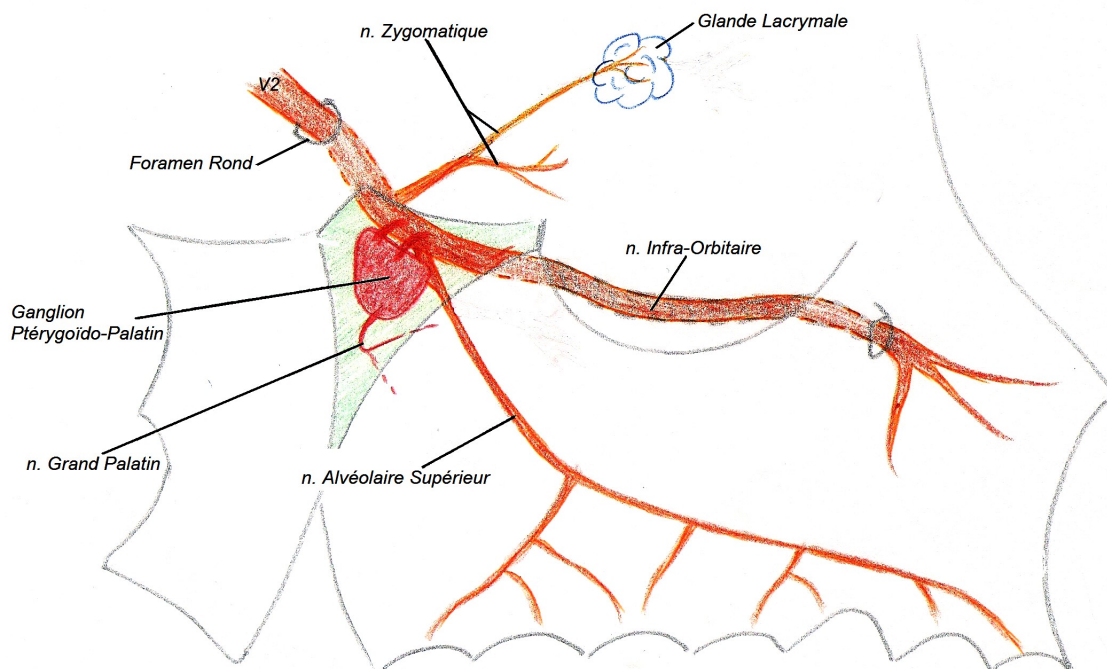
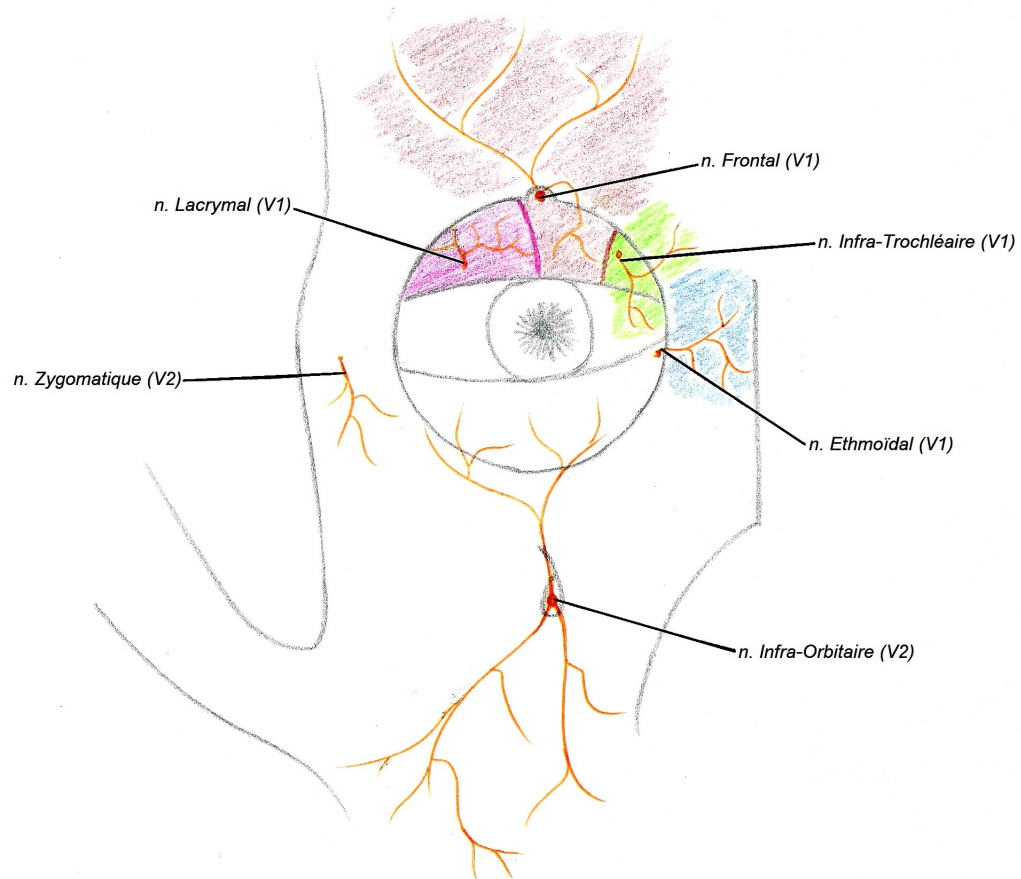




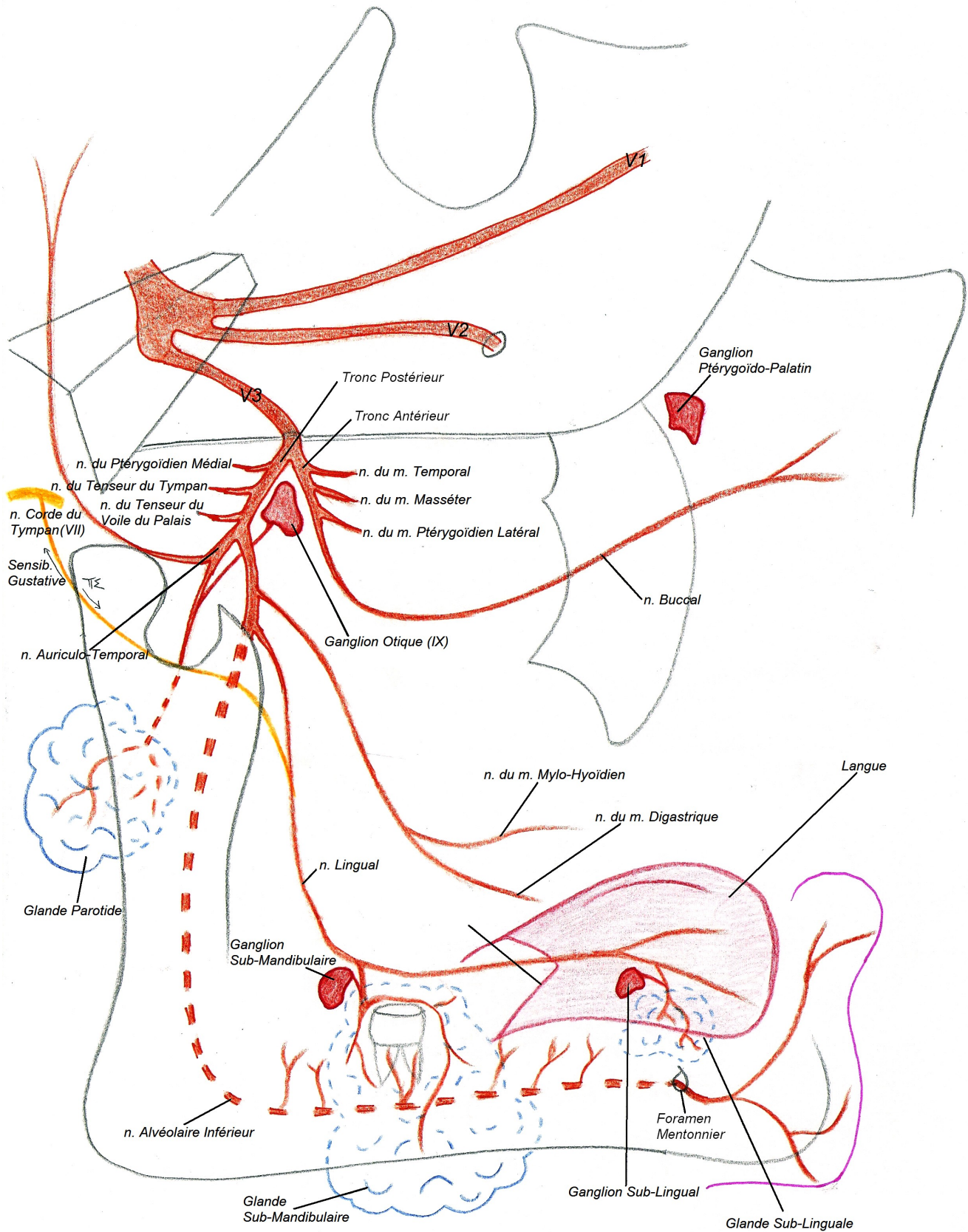
COUPE FRONTALE DU CORPS DU SPHENOÏDE

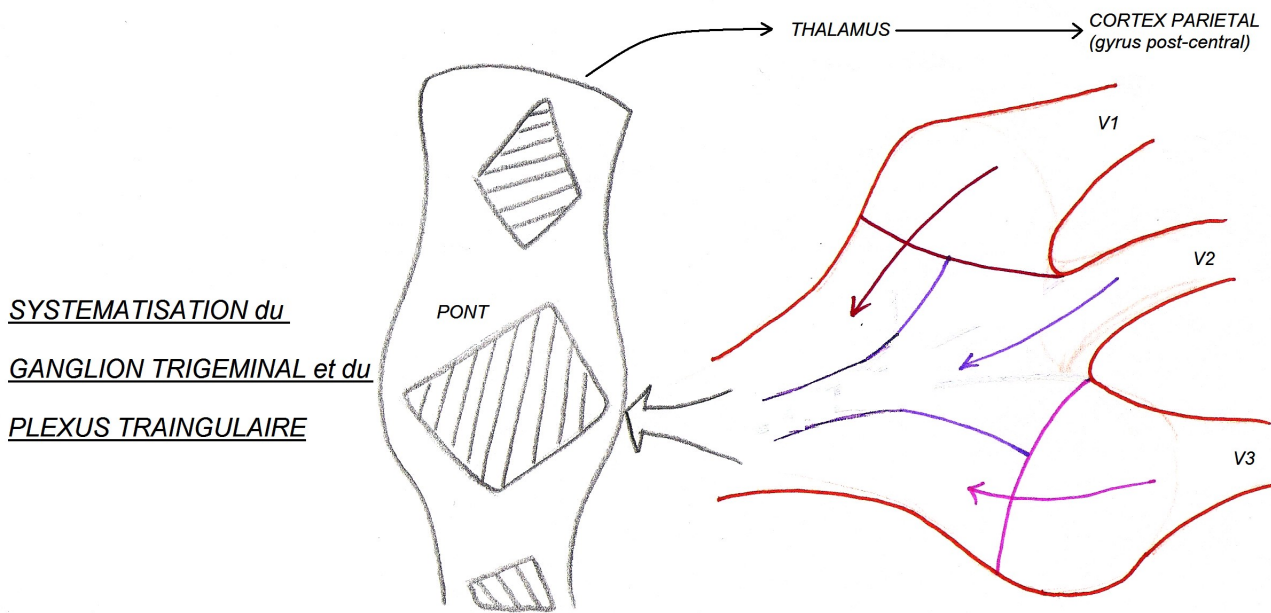
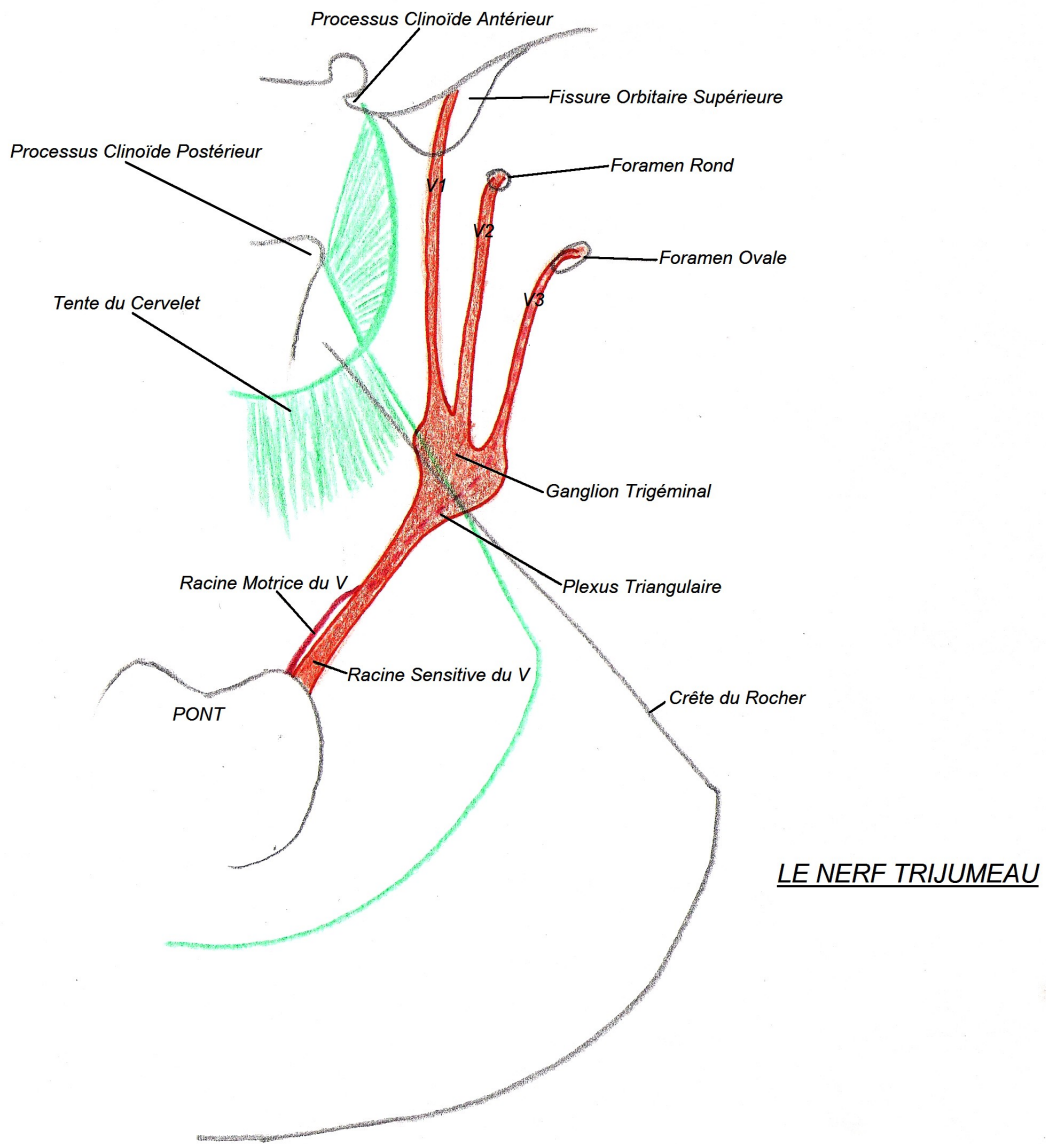


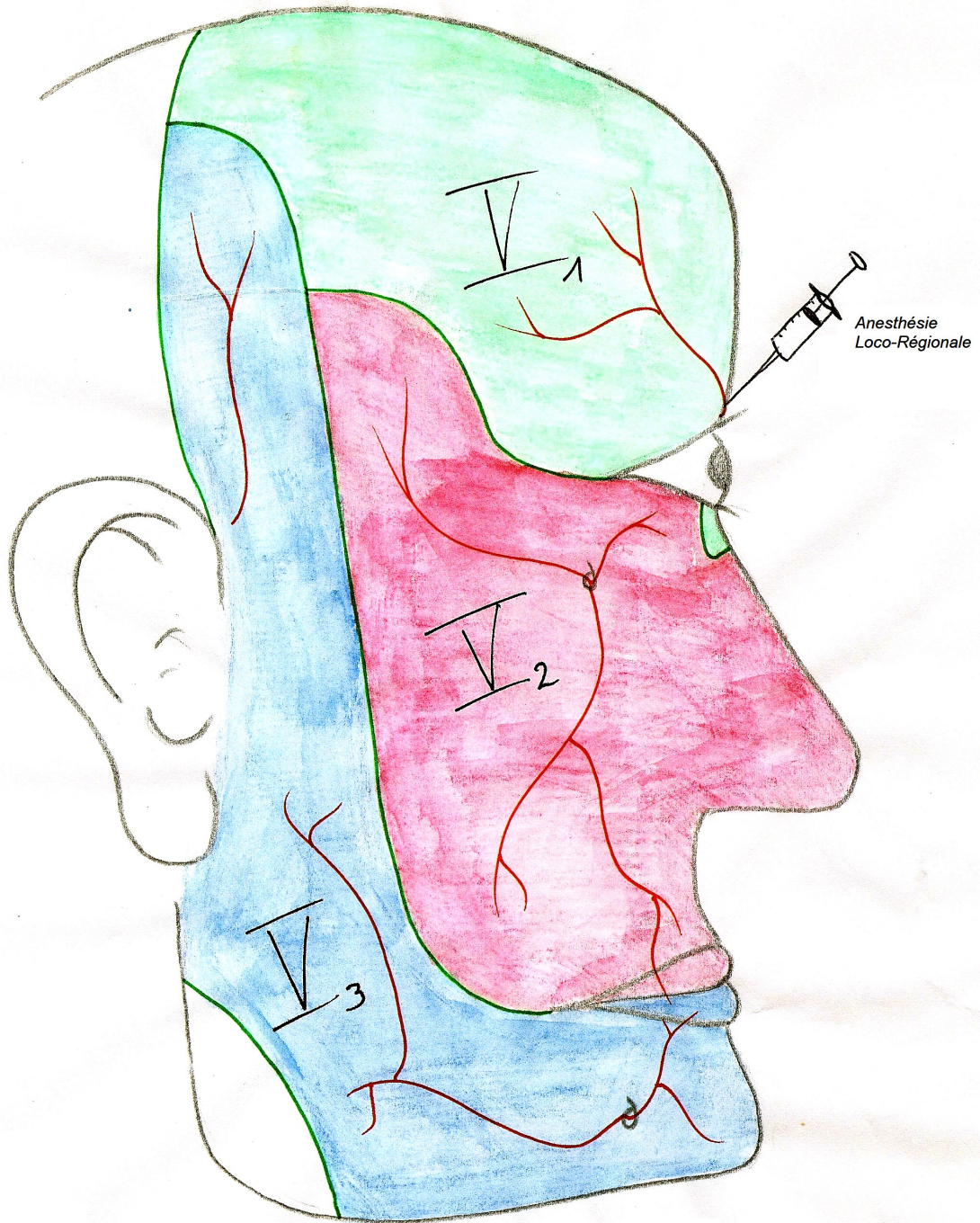




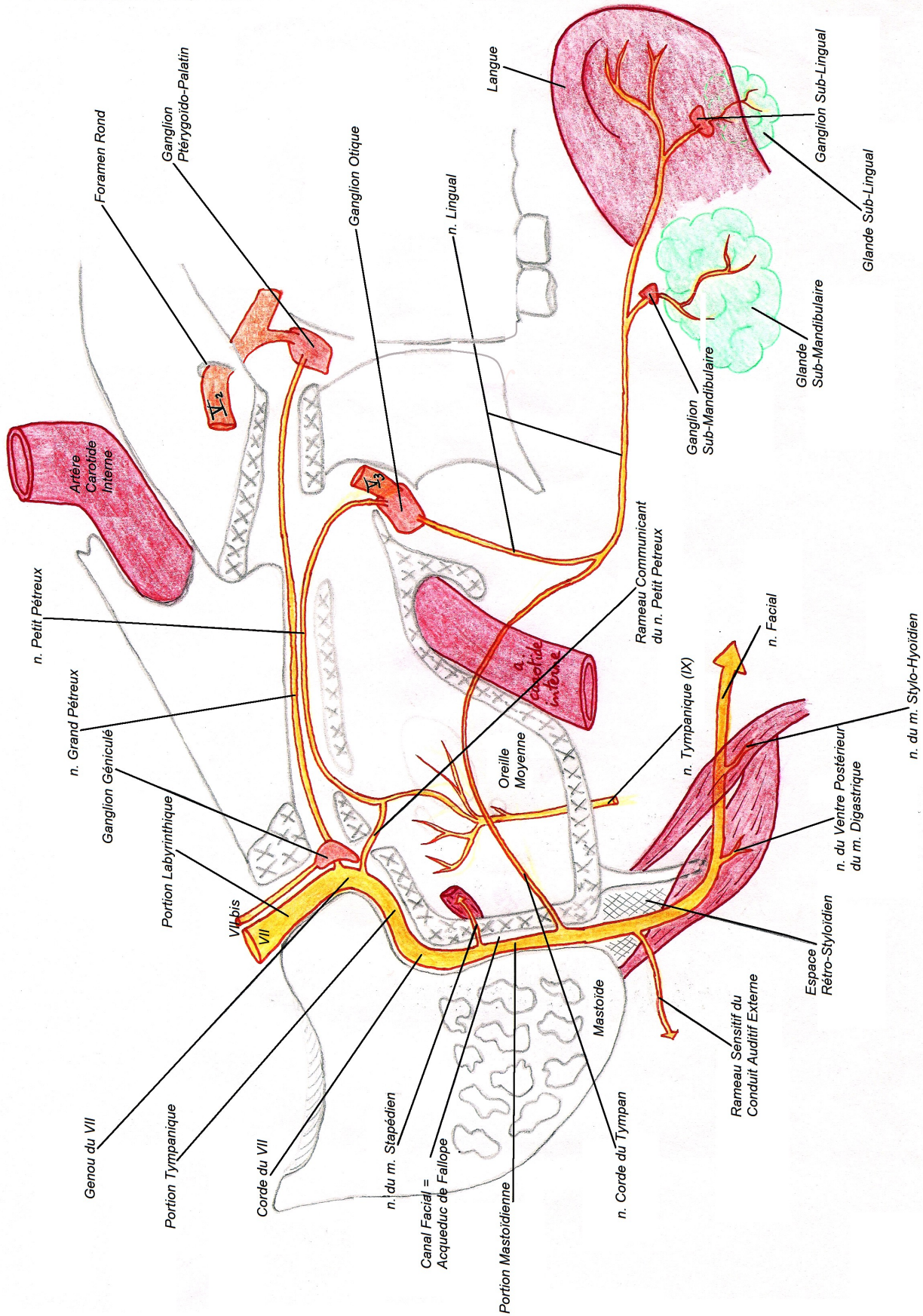
LE NERF MANDIBULAIRE (V3)



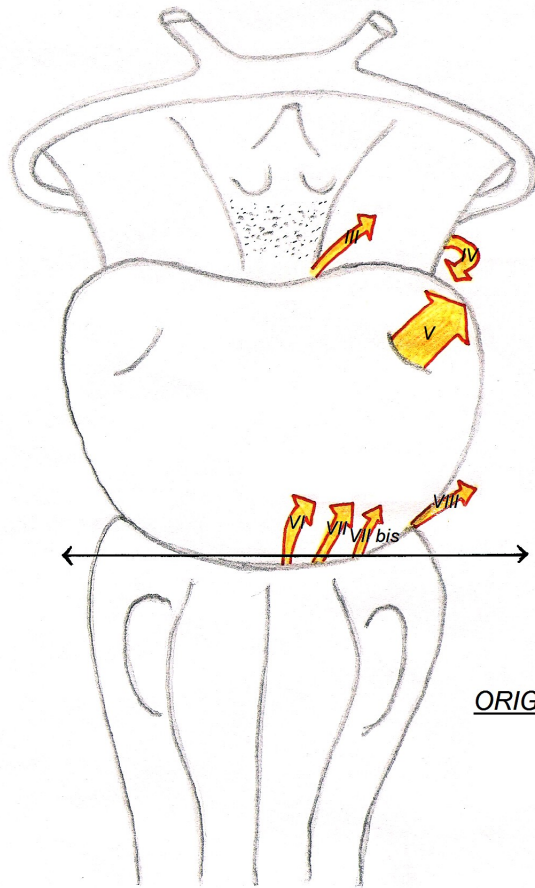




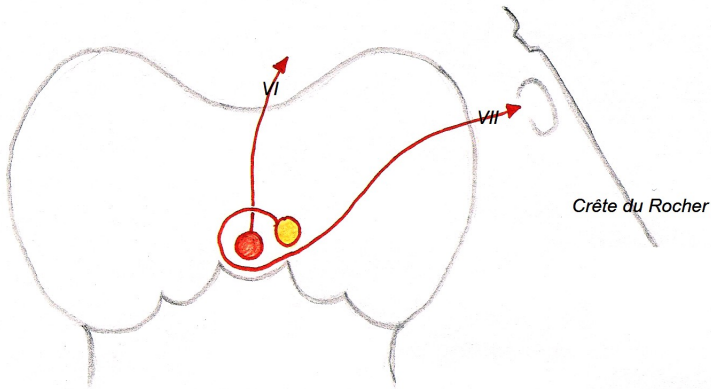
REPARTITION du V pour la SENSIBILITE de la FACE



Le NERF VII INTRA-PÉTREUX

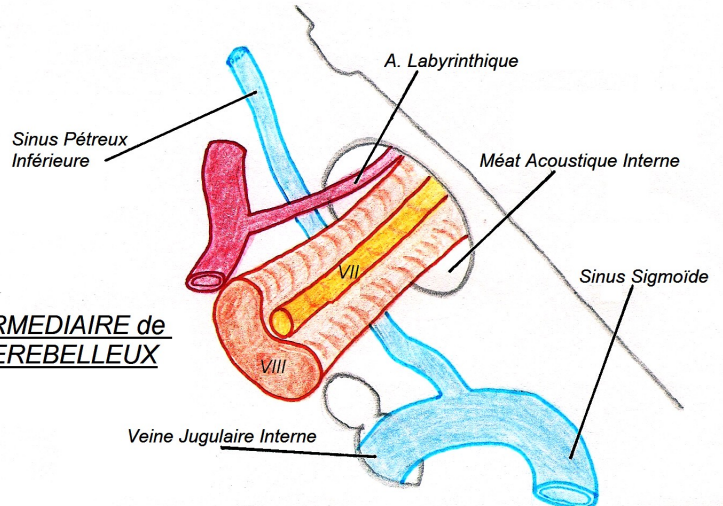


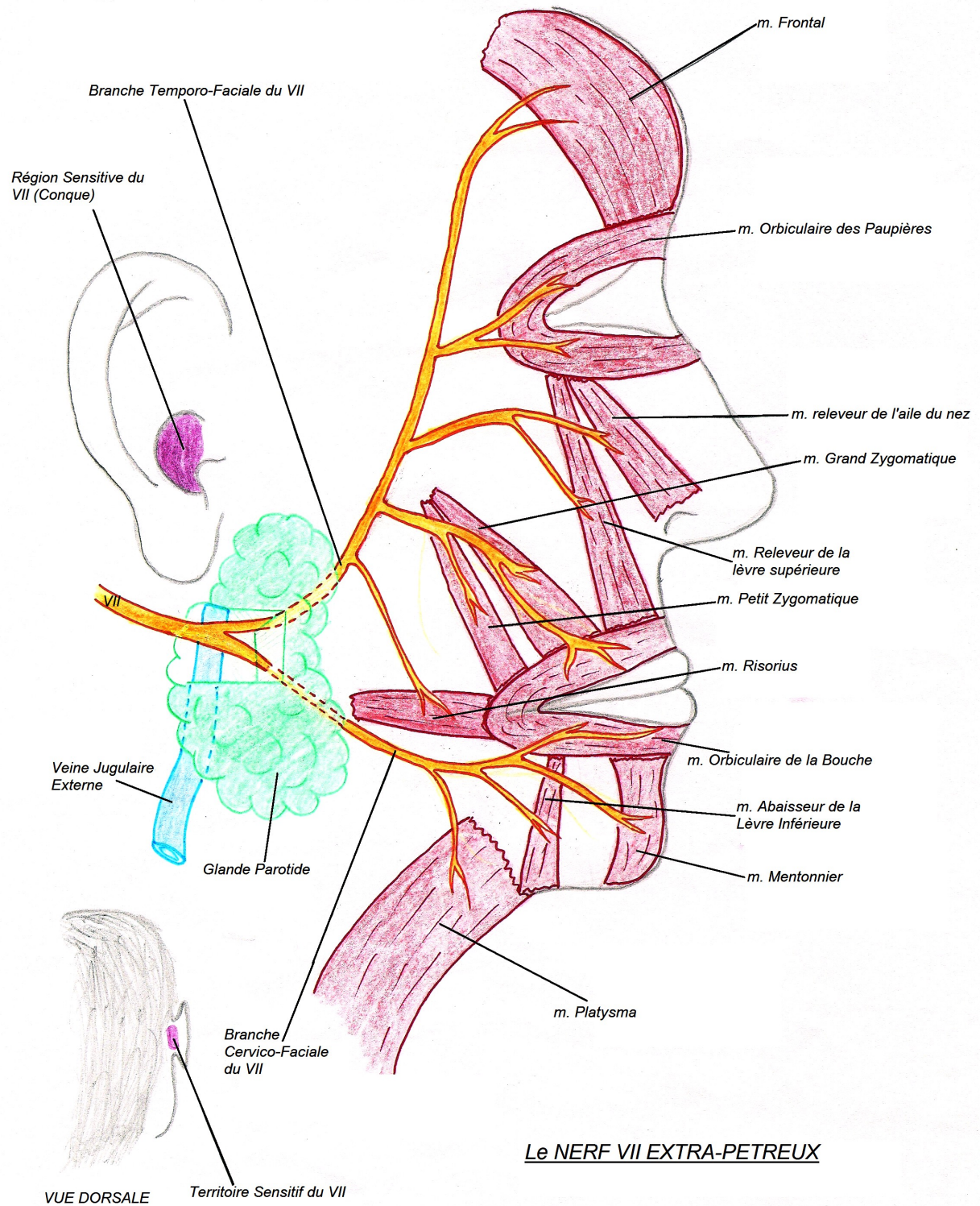
ORIGINE APPARENTE du VII
(vue ventrale du tronc)

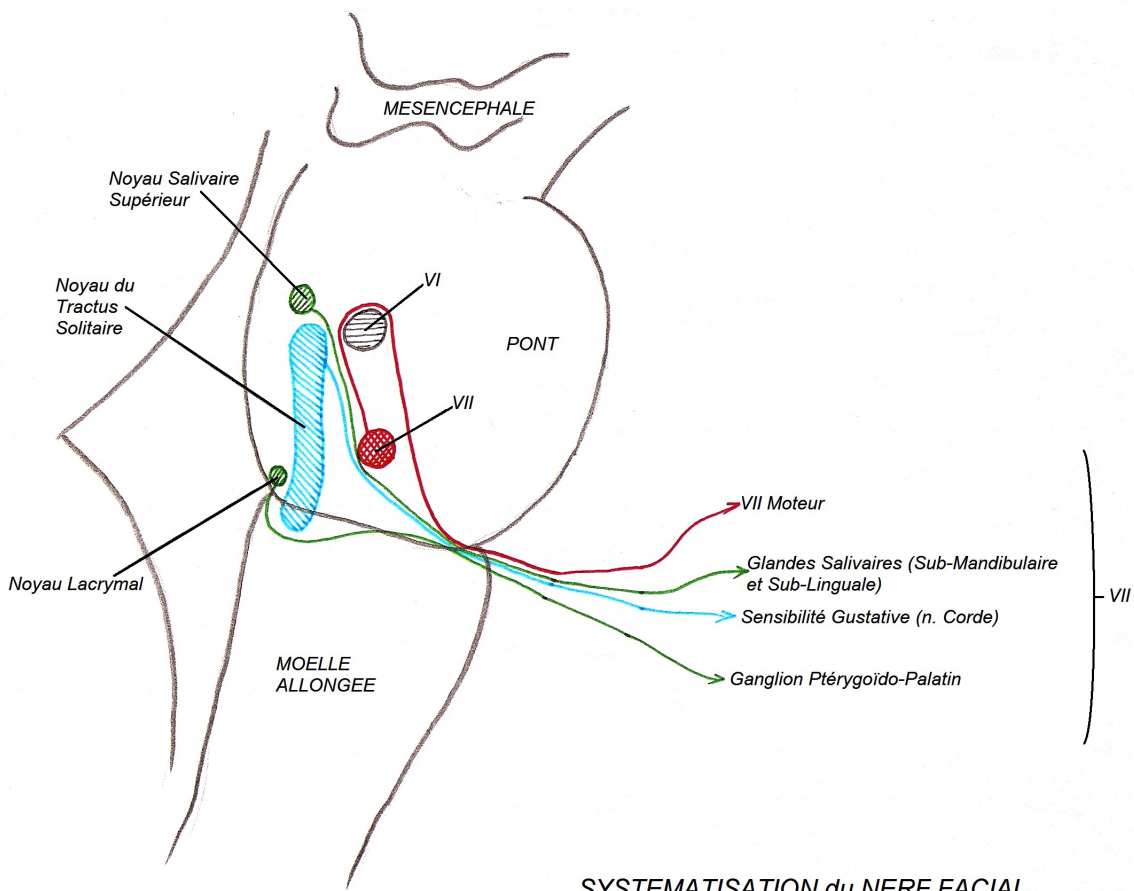
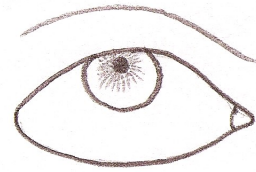
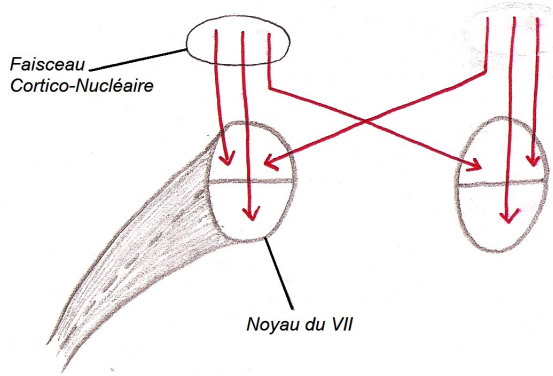


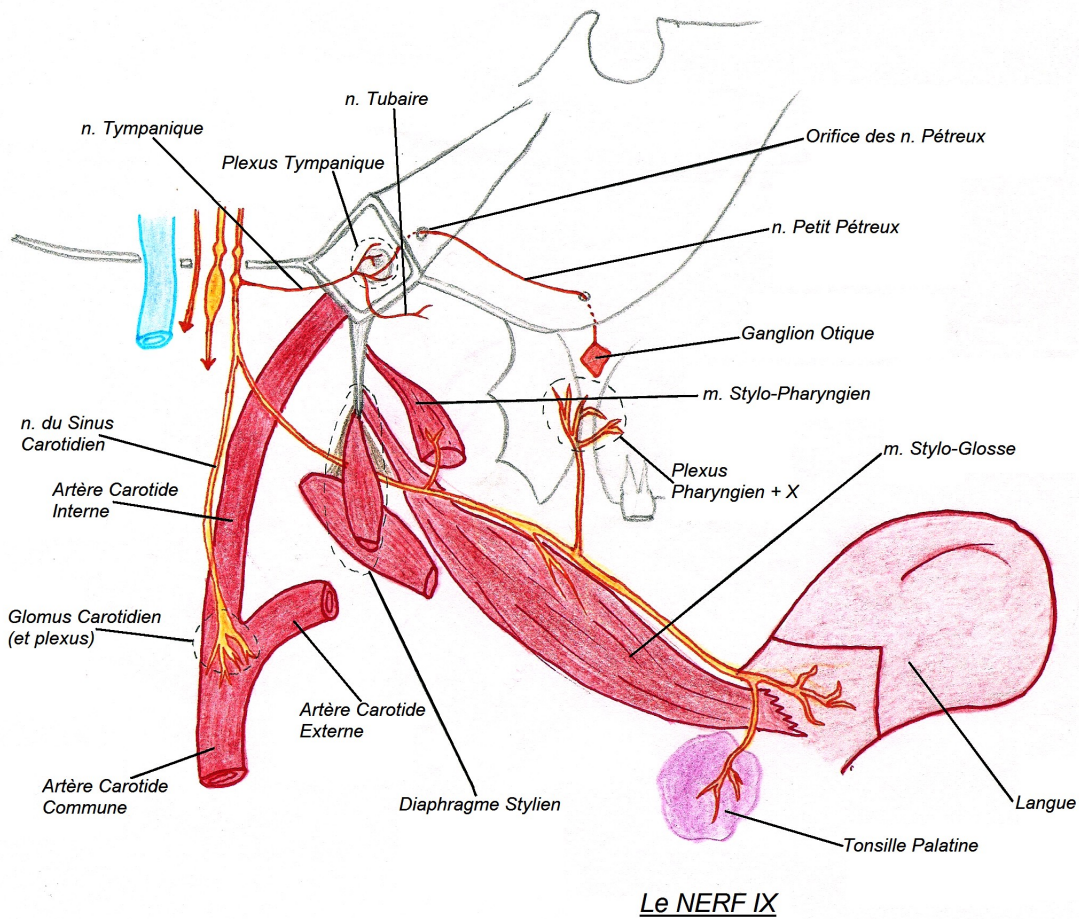
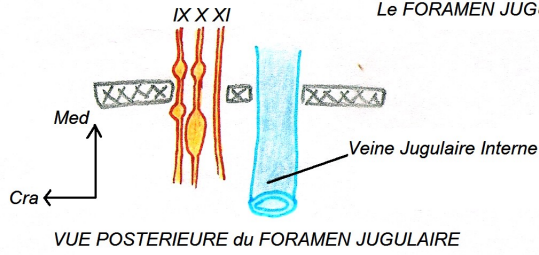
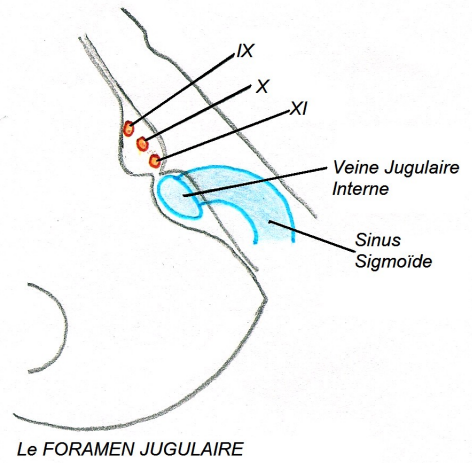
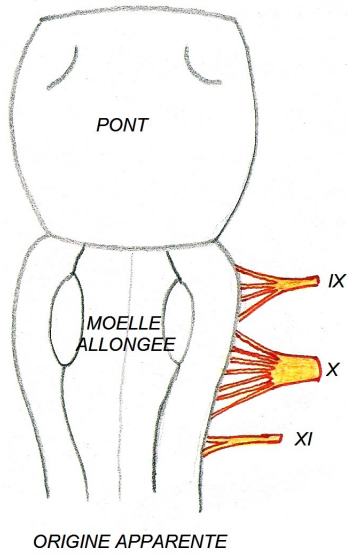
COUPE TRANSVERSALE du PONT

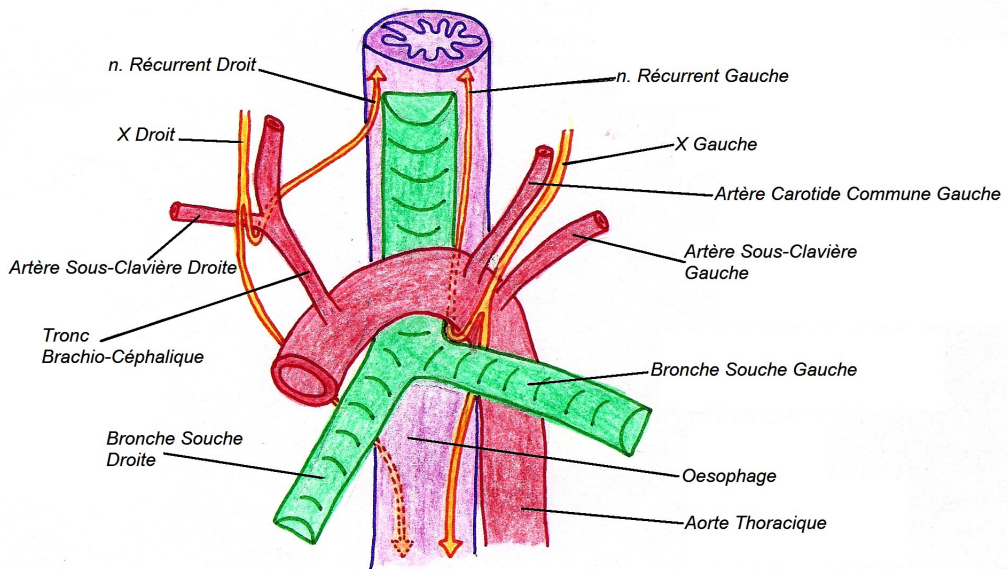
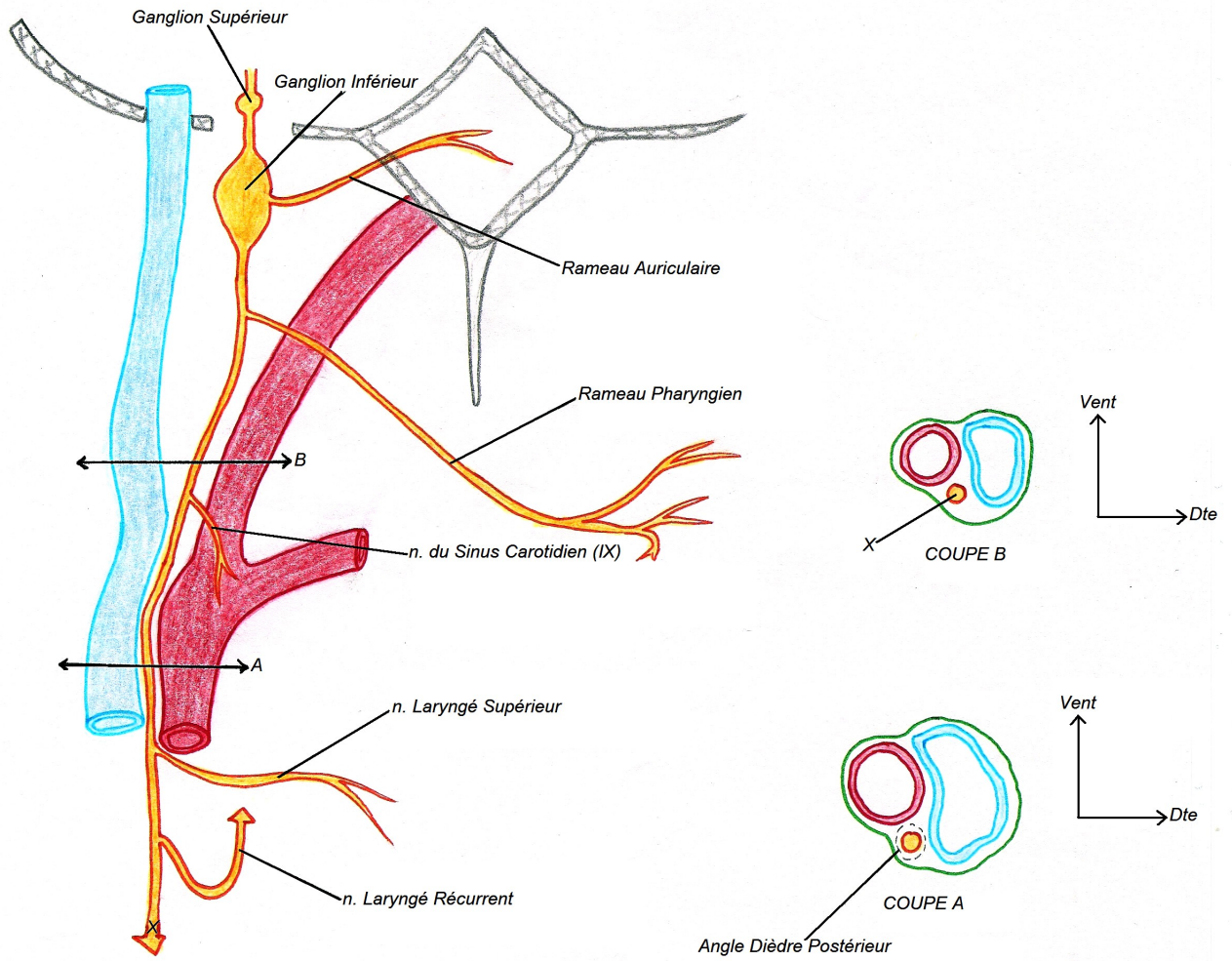
Le PEDICULE INTERMEDIAIRE de
L'ANGLE PONTO-CEREBELLEUX



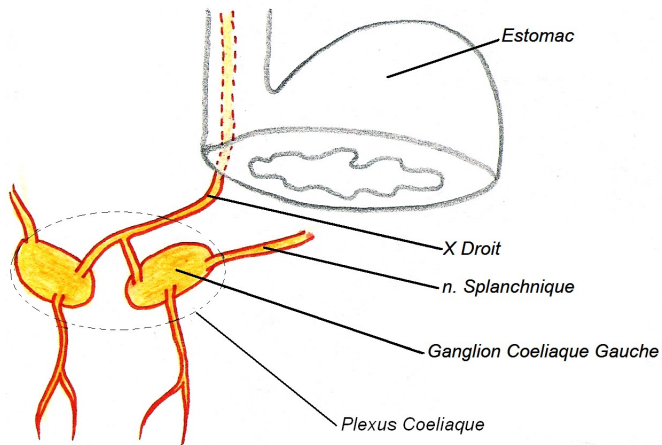




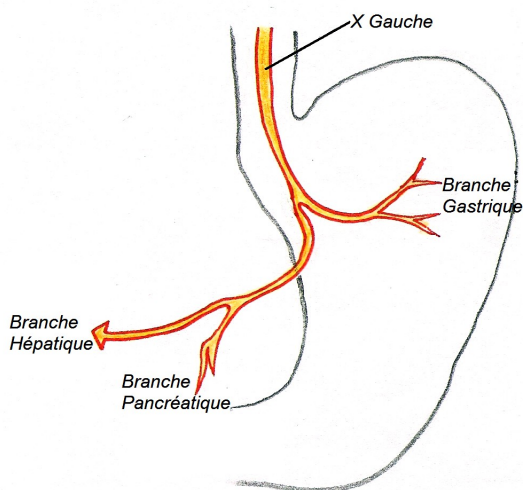




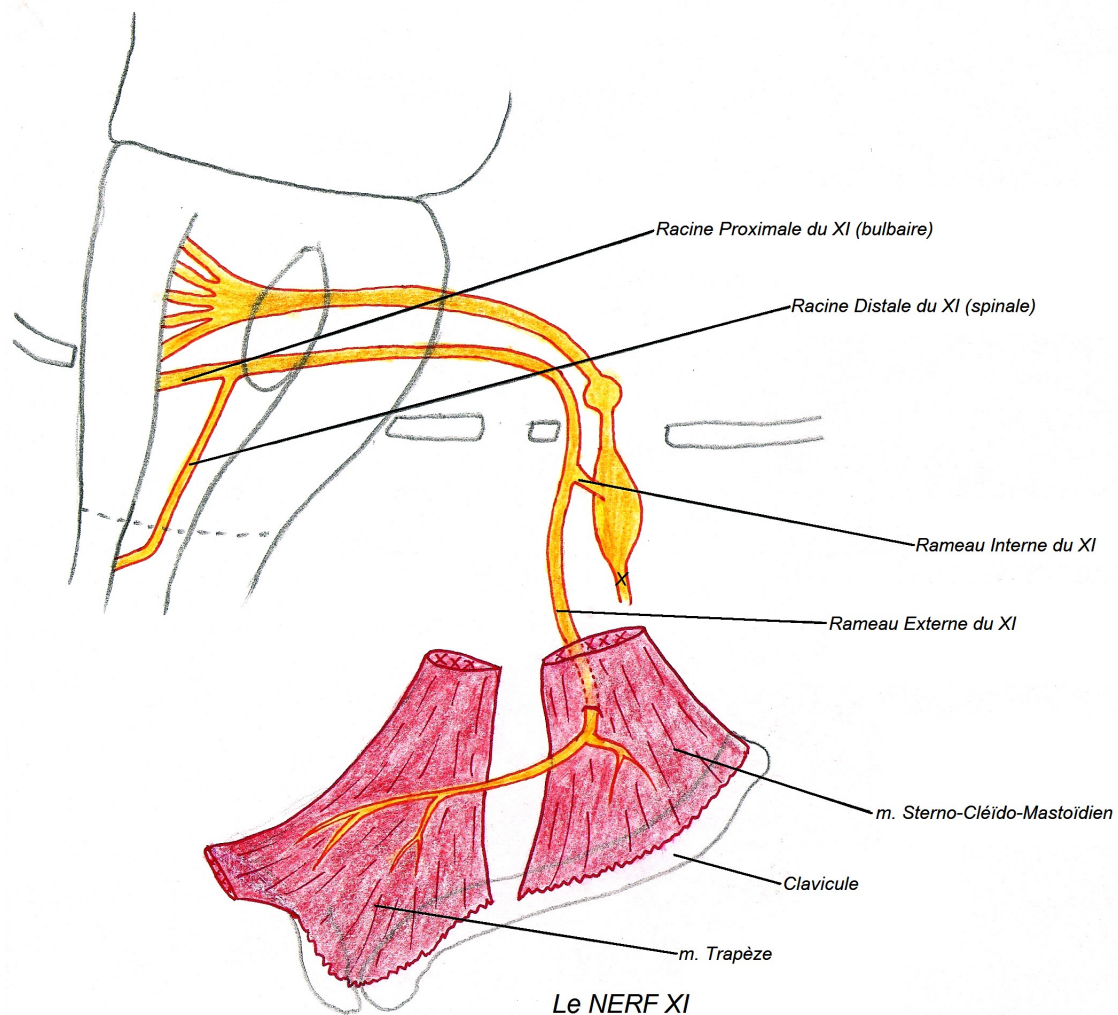
Les NERFS RECURRENTS



Le X DROIT



Le X GAUCHE



Le NERF XI